Institut für Tierpathologie der Vetsuisse-Fakultät Universität Bern
Zentrum für Fisch- und Wildtiermedizin
(Leiter: Prof. Dr. H. Segner)

Arbeit unter der Leitung von
Dr. D. Bernet

Gonadenveränderungen bei Thunersee-Felchen (Coregonus spp.) – eine Folge von endokrin aktiven Substanzen?

Inaugural-Dissertation

zur Erlangung der Doktorwürde
der Vetsuisse-Fakultät Universität Bern

vorgelegt von

Sibylle Kipfer
von Lützelflüh, BE

2008

Von der Vetsuisse-Fakultät Universität Bern auf Antrag
von Prof. Dr. H. Segner als Dissertation genehmigt.

Bern,

Der Dekan der
Vetsuisse-Fakultät Universität Bern

INHALTSVERZEICHNIS

DANK

Hiermit möchte ich allen danken, die zum Gelingen dieser Arbeit beigetragen haben und die mir das Arbeiten hier am FiWi leicht und schön gemacht haben. Besonders bedanke ich mich bei:

Prof. Dr. Maja Suter für die freundliche Aufnahme am Institut.

Prof. Dr. Helmut Segner für die ideenreichen Diskussionen, anregenden Anmerkungen und das Übersicht-Behalten und Sich-Zeit-Nehmen trotz den vielen laufenden Projekten.

Dr. Daniel Bernet für die exzellente Betreuung während meiner gesamten Dissertationszeit, für die klar durchdachten Konzepte, für die praktischen Anweisungen, für alle Unterstützung in der Statistik und für die angenehme Zusammenarbeit.

Dr. Thomas Wahli für die grosse Hilfsbereitschaft bei allen auftretenden Fragen und die Hilfe bei den Probenahmen.

Dr. Heike Schmidt für die Schärfung des Sehsinnes in Sachen Histologie.

Michael Wenger und Barbara Müller für die wertvollen Tipps und Tricks im Labor und auch für die Mithilfe bei der Fischbetreuung und bei den Probenahmen.

Den jetzigen und ehemaligen Mitarbeitern und Doktoranden des FiWis, Katarina, Katrin, My, Anja, Ayako, Lucia, Elisabeth, Dmitri, Richard, Ralph, Nelson, Manuela, Stefan, Nadja und Marie-Pierre für das angenehme Arbeitsklima und die vielfältigen Gespräche.

Den Mitarbeitern des Histolabors für die effiziente Bereitstellung der Histoschnitte.

Meiner Familie und meinen Freunden, die mein Leben immer wieder bereichern und auf die ich in jeder Situation zählen kann.

1. EINLEITUNG

Felchen (*Coregonus spp.*) sind die mit Abstand am häufigsten gefangene Fischart (20-50 t/a) im Thunersee, Kanton Bern, Schweiz. Der Thunersee ist ein oligotropher voralpiner See mit einer Grösse von 47 km^2 und einer Tiefe bis 217 m. Vier verschiedene Felchen-Ökotypen leben sympatrisch in unterschiedlichen Nischen des Sees: Albock, Brienzlig, Kropfer und Balchen. Morphologisch lassen sich die vier Ökotypen am besten durch die unterschiedliche Anzahl an Kiemenreusendornen unterscheiden.

Im Jahr 2000 beobachteten Berufsfischer des Thunersees erstmals eine beachtliche Anzahl Felchen mit auffälligen Veränderungen an den Gonaden. In früheren Jahren wurden solche Veränderungen nicht beobachtet. Das plötzliche Erscheinen und das gehäufte Auftreten der Veränderungen gab Anlass zur Besorgnis. Die Ursachen der Veränderungen waren unbekannt. Ebenso konnten die Auswirkungen und Konsequenzen der Veränderungen, sowohl für die Felchenpopulation, als auch für die Trinkwassergewinnung aus dem See (der See dient als Trinkwasserquelle für rund 500‘000 Personen) nicht abgeschätzt werden.

Das Fischereiinspektorat des Kantons Bern hat das Zentrum für Fisch und Wildtiermedizin (FIWI) beauftragt, die Felchen pathologisch zu untersuchen und die Veränderungen zu charakterisieren (Bernet et al. 2004). In Zusammenarbeit mit dem Fischereiinspektorat wurde ein Überwachungsprogramm initiiert, bei dem monatlich 25 Fische aus dem Thunersee auf Gonadenveränderungen beurteilt wurden. 35% der insgesamt 808 beprobten Felchen wiesen Veränderungen in ihren Geschlechtsorganen auf. Männchen (40%) waren signifikant häufiger betroffen als Weibchen (26%). Unterteilungen (11%) waren am häufigsten, gefolgt von Verwachsungen (5%), Asymmetrien (4%), Atrophien/Aplasien (4%), Einschnürungen (3%) und Intersexgonaden (1.1%). Gonadenveränderungen traten in allen Altersklassen auf, wurden jedoch am häufigsten bei den 3- bis 5-jährigen Tieren beobachtet. Brienzlig (43%) und Kropfer (47%) waren häufiger betroffen als Albock/Balchen (29%).

Die Ursachen der hohen Häufigkeit von Gonadenveränderungen bei Thunersee-Felchen sind umstritten. Die Jungfischaufzucht in der Fischzucht als Ursache für die Gonadenveränderungen kann ausgeschlossen werden, weil nur die Albock Morphe in der Fischzucht aufgezogen und anschliessend im Thunersee besetzt wird, diese jedoch weniger betroffen ist als Brienzlig und Kropfer. Ebenfalls konnten Parasiten als Ursache ausgeschlossen werden.

Eine wichtige Information, die im Hinblick auf eine Ursachenanalyse der Gonadenveränderungen im Thunersee fehlte, ist das Wissen um mögliches Auftreten von

Gonadenveränderungen bei Felchen in anderen Schweizer Seen. Das Überwachungsprogramm wurde in den folgenden Jahren auf die beiden benachbarten Seen Brienzersee und Bielersee ausgedehnt. Man stellte fest, dass die im Thunersee beschriebenen Veränderungstypen auch bei Felchen im Brienzer- und Bielersee gefunden wurden, insgesamt aber deutlich seltener waren (Bittner et al., eingereicht). Einschnürungen und Asymmetrien kamen sogar in vergleichbarer Häufigkeit vor. Sie scheinen daher eine „natürlich“ vorkommende Variabilität in der Gonadenmorphologie zu repräsentieren. Im Gegensatz dazu waren Verwachsungen, Unterteilungen, einseitig fehlende Gonaden (v.a. bei Weibchen), sowie Intersexgonaden signifikant seltener, als im Thunersee. Sie repräsentieren daher die „echten“ Gonadendeformationen bei den Thunerseefelchen.

Morphologische Gonadenveränderungen bei Fischen wurden auch schon in anderen Studien weltweit beschrieben (Norrgren et al. 1994, Hunter & Macewicz 1995, Kinnison et al. 2000, Blazer 2002, Mikaelian et al. 2002). Die beschriebenen Veränderungen betrafen v.a. Intersexgonaden, aber auch Gonadentumore und Parasitenbefall. In den meisten Fällen konnten jedoch die Ursachen für die Veränderungen nicht ermittelt werden, bzw. wurden nur Mutmassungen angestellt. Bekannt sind eine Reihe von Faktoren, welche die Gonadenmorphologie und –entwicklung beeinflussen können. Dazu zählen Wassertemperatur (Patino et al. 1996, Baroiller et al. 1999, Goto et al. 1999, Kitano et al. 1999), Parasitenbefall (Wiklund et al. 1996, Jobling & Tyler 2003) und Umweltchemikalien (Kime 1995, Jobling et al. 1998, Noaksson et al. 2001). Ein Umweltfaktor, der in den letzten Jahren besondere Aufmerksamkeit als Ursache von morphologischen Gonadenveränderungen bei Fischen gefunden hat, sind hormonaktive Substanzen (endocrin-disrupting chemicals = EDCs). EDCs sind natürliche oder künstliche Substanzen, die mit dem endokrinen System des Organismus interferieren und in den Hormonhaushalt eingreifen. Sie verstärken oder hemmen (i) die Produktion und/oder (ii) die Wirkung der körpereigenen Hormone oder Proteine im Organismus und/oder (iii) beeinflussen deren Metabolismus. Oft funktionieren sie als Östrogenrezeptorliganden und aktivieren dadurch Östrogensignalwege (Segner et al. 2003, Porte et al. 2006, Matozzo et al. 2007).

Ziel der vorliegenden Arbeit war, die Hypothese zu prüfen, dass EDC bei der Ausbildung der Gonadenveränderungen der Felchen im Thunersee beteiligt sind. Dazu wurden zwischen 2004 und 2007 zwei mehrjährige Laborexperimente und ein Überwachungsprogramm bei den freilebenden Wildfischen im Thunersee durchgeführt. Im ersten Laborversuch („E2 Fütterungsversuch“) wurde untersucht, ob östrogen wirksame Stoffe die Thunersee-typischen Gonadenveränderungen induzieren können. Für diese Fragestellung wurden Felchen vom Schlupf bis zur Geschlechtsreife über drei Jahre aufgezogen und täglich mit

17-β-Östradiol (E2) angereichertem Futter gefüttert. E2 ist das körpereigene, weibliche Geschlechtshormon und diente im Versuch als Modellsubstanz für EDCs. Ein weiterer Laborversuch („Ontogeniestudie“) hatte zum Ziel, (a) die ontogenetische Entwicklung der Felchengonaden unter Kontrollbedingungen zu charakterisieren, da bisher keine publizierten Daten zur Gonadenentwicklung der Felchen vorliegen, und (b) zu untersuchen, ob die Gonadenveränderungen sich während oder nach der Gonadenentwicklungsphase bilden. Für diese Fragestellung wurden Felchen vom Schlupf bis zur Geschlechtsreife in der Fischzucht aufgezogen und regelmässig beprobt. Dieser Versuch liefert Grundlageninformationen über den Beginn des Differenzierungsprozesses und damit über die Dauer der sensiblen Phase für EDC-Einflüsse im Entwicklungsprozess. Der dritte Teil der Dissertation, das „Überwachungsprogramm“, schliesslich hatte zum Ziel, bei wildlebenden Felchen aus dem Thunersee drei verschiedene Biomarker für Exposition an hormonaktive Substanzen zu messen. Damit soll geklärt werden, ob die wildlebenden Fische im Thunersee hormonaktiven Substanzen ausgesetzt sind.

2. MATERIAL UND METHODEN

2.1. E2 Fütterungsversuch

Eier von Felchen der Albock Morphe wurden künstlich befruchtet und in der kantonalen Fischzuchtanlage Reutigen in Quellwasser in Zugergläsern erbrütet. Im Alter von 87 Tagen wurden die Brütlinge ans Zentrum für Fisch- und Wildtiermedizin transferiert, an das Leitungswasser und das Futter adaptiert und in drei Gruppen von je 145 Tieren eingeteilt. Ab dem Alter von 122 Tagen nach Schlupf wurde begonnen, die Fische 17β-Östrogen (Estrogen (2,4,16,16-D4, 95-97%); DLM-2487-0; Cambridge Isotope Laboratories, Inc., Andover, USA) zu exponieren. Das Östrogen wurde dem Futter (Trockenpellets) zugemischt und oral verabreicht. Die eine Gruppe erhielt eine Tagesdosis von 50 µg E2 kg^{-1} Fisch (High dose Gruppe), die zweite 0.5 µg E2 kg^{-1} Fisch (Low Dose Gruppe) und die dritte diente als Kontrollgruppe und erhielt keine E2 Zusätze. Die Fische wurden bis zum Erreichen der Geschlechtsreife während annähernd 3 Jahren, bis zu einem Alter von 960 Tagen nach Schlupf, aufgezogen.

Aus allen drei Gruppen wurden Fische zu den Zeitpunkten 42, 77, 347 und 838 Tage nach Beginn der E2 Zufütterung im Alter von 136, 164, 191, 469 und 960 Tage nach Schlupf beprobt. Die Fische wurden mit einer Überdosis Tricaine Methansulfonat, Finquel MS 222 (Argent Chemical Laboratories, Redmont, WA, USA) getötet, gemessen und gewogen und

eröffnet. Die Gonaden wurden morphologisch gemäss den Kriterien von Bernet et al (2004) bewertet und histologisch auf Reifegrad und Vorhandensein von Intersex beurteilt. Bei männlichen und Intersex Fischen wurde der Gehalt von mRNA Vitellogenin (VTG) in der Leber – dem Vorläuferprotein des Eidotters – mittels einer Real-time RT-PCR bestimmt.

2.2. Ontogenie der Felchen

Eier von Felchen der Albock Morphe wurden künstlich befruchtet, und in der Fischzuchtanlage Faulensee in Thunerseewasser, bzw. in der kantonalen Fischzucht Reutigen in Quellwasser mit der Zugerglas-Methode erbrütet. Nach dem Schlupf wurden die Brütlinge im Thunerseewasser mit Plankton aus dem Thunersee und diejenigen in Reutigen mit kommerziellen Trockenpellets gefüttert und bis zur Geschlechtsreife während 3 Jahren aufgezogen. Die Wassertemperaturen des Thunerseewassers folgte den saisonalen Schwankungen und bewegte sich zwischen 5-22°C. Die Fische im Quellwasser der Fischzucht Reutigen schwammen in konstanter Wassertemperatur von 8-9°C.

Die Fische der beiden Gruppen wurden regemässig beprobt: In den ersten 5 Monaten wöchentlich, und danach monatlich bis zwei-monatlich. Pro Probenahme wurden 15-20 Fische mit einer Überdosis Tricaine Methansulfonat, Finquel MS 222 (Argent Chemical Laboratories, Redmont, WA, USA) getötet, gemessen und gewogen und eröffnet. Die Gonaden wurden morphologisch gemäss den Kriterien von Bernet et al. (2004) bewertet und histologisch auf Reifegrad und Vorhandensein von Intersex beurteilt.

2.3. Überwachungsprogramm

Im September und Dezember 2005 und 2006 wurden insgesamt 878 Felchen aus dem Thunersee beprobt. Die Fische wurden während der Laichzeit mit Bodennetzen an vier verschiedenen Laichplätzen verteilt über den ganzen See, gefangen. An zwei Laichplätzen (Merligen und Faulensee) wurde die Felchen-Morphe Brienzlig gefangen. An den beiden anderen Plätzen (Schifflätti und Gwatt) wurden Albock gefangen. Albock und Brienzlig unterscheiden sich morphologisch am deutlichsten durch die Anzahl Kiemenreusendornen. Das Diskriminierungsmerkmal ist aber nicht 100% verlässlich, weil es überlappende Bereiche gibt. Durch ihre zeitlich unterschiedlichen Laichtermine (Brienzlig im September und Albock im Dezember) konnten die beiden Morphen einwandfrei unterschieden werden. Die Fische wurden mit Kopfschlag getötet und eröffnet. Die Gonaden wurden morphologisch gemäss den Kriterien von Bernet et al (2004) bewertet. Zusätzlich wurden bei den Fischen drei unterschiedliche Biomarker für EDCs untersucht:

Vitellogenin (VTG): VTG-Induktion ist ein gut etablierter Biomarker, um bei männlichen Fischen eine Exposition an Östrogenrezeptor-Liganden festzustellen (Sumpter & Jobling 1995). Wir massen hepatische VTG mRNA mittels einer real-time RT-PCR in einem ABI7300 PCR System, welches ein 800 bp langes Fragment des VTG Gens amplifiziert.

Sexualsteroide: Beeinträchtigungen des Sexualsteroidmetabolismus und des Sexualsteroidspiegels im Blut wurden wiederholt in Fischen beobachtet, welche Störungen im endokrinen System zeigten, z.B. bei Zellstofffabrikabwässer exponierten Fischen (McMaster et al. 1991). Wir massen Testosteron und 11-Ketotestosteron in männlichen Fischen mittels eines kommerziellen ELISA kits (Cayman Chemical Company, Ann Arbor, MI, USA).

Intersexhäufigkeit: Eine häufig dokumentierte pathologische Veränderung, als Reaktion auf EAC Exposition, ist die Entwicklung von Ovotestis, d.h. Gonaden mit vorwiegend testikulärer Morphologie, aber auch mit darin vorhandenen Oozyten (z.B. Jobling et al. 1998; van der Ven et al. 2003, Leino et al. 2005). Wir untersuchten die Gonaden histologisch, um die Zitterhäufigkeit zu bestimmen.

3. RESULTATE

3.1. E2 Fütterungsversuch (siehe Kapitel A)

E2 führte zu einer dosisabhängigen Zunahme der mikroskopischen Intersexhäufigkeit. Sowohl die Intersexhäufigkeit, als auch die -intensität nahm mit fortschreitender Expositionsdauer zu. Die Intensitätszunahme war durch die unterschiedliche Präsenz der vier verschiedenen Intersex-Typen im Verlauf der Exposition erkennbar. Typ 1 bestand aus testikulärem Gewebe, in welches einzelne Oozyten eingestreut waren. Bei Typ 2 wies das Hodengewebe Ovar-ähnliche Lamellenstrukturen auf. Im Typ 3 lag auf der Gonade sowohl testikuläres (≤ 50% Flächenanteil), als auch ovarielles Gewebe (≥ 50%) vor. Bei Typ 4 dominierte das ovarielle über das testikuläre Gewebe. Einige Weibchen zeigten unilateral atrophische Gonadenstränge. Andere bei den Thunersee-Felchen beschriebene Gonadendeformationen wurden hingegen durch die E2 Verfütterung nicht induziert.

Die orale E2-Verabreichung führte zu bekannten endokrin-disruptiven Effekten: Verschiebung des Geschlechterverhältnisses zugunsten der Weibchen, Reduktion des Konditionsfaktors und des Gonadenwachstums mit verzögerter Keimzellentwicklung und Akkumulation von Vitellogenin in Leber, Niere, Herz und Gonaden.

Die hormonaktive Wirkung der E2 Verfütterung auf die Fische wurde anhand der VTG mRNA Expression mittels einer real-time RT-PCR gemessen und bestätigt.

E2-exponierte Felchen zeigten verschiedene bekannte Biomarker für endokrine Disruption. Durch E2 Verfütterung konnten die Thunersee-typischen makroskopischen Gonadenveränderungen jedoch nicht induziert werden. EDCs als Ursache für die Gonadenveränderungen bei den Felchen im Thunersee erscheinen daher unwahrscheinlich.

3.2. Ontogenie der Gonaden der Felchen (siehe Kapitel B)

Undifferenzierte Gonadenanlagen wurden erstmals 65 Tage nach Schlupf beobachtet, respektive nach 491 Tagesgraden (d°C). Die Differenzierung der Ovarien (Start von 1734 bis 1820 d°C) geschah früher als die Differenzierung der Hoden (Start von 1989 - 3673 d°C). Während dieser Zeit sind die Fische besonders empfindlich auf endogene Einflussfaktoren, welche mit dem Hormonsystem interagieren. Die testikuläre Differenzierung war kontinuierlich, ohne Ruhephasen, wie sie in der Ovarentwicklung zwischen der Kortikoalveolär-Phase und dem Auftreten von vitellogenen Oozyten vorkamen. In beiden Geschlechtern wurden die ersten reifen Keimzellen mit 8163 - 8356 d°C gefunden. In Bezug auf das Alter war die Gonadenentwicklung der in unbelastetem Quellwasser aufgezogenen Gruppe deutlich später, als bei der in Thunerseewasser aufgezogenen Gruppe. In Bezug auf die Fischgrösse fand die Gonadenentwicklung der in Thunerseewasser aufgezogenen Felchen jedoch früher statt als in den Felchen, welche im Quellwasser aufgezogen wurden. In Bezug auf die Tagesgrade (d°C) wiesen die Gonaden der beiden Gruppen einen gleich weiten Entwicklungsstand auf.

Es zeigte sich, dass verschiedene morphologische Gonadenveränderungen bereits früh in der Gonadenentwicklung auftraten. Einschnürungen und Asymmetrien kamen erstmals im ersten oder zweiten Lebensjahr vor. Aplasien und Unterteilungen hingegen wurden erst im dritten Lebensjahr beobachtet. Intersexgonaden traten bei 8-9% der Fische auf, was auf ein natürlich gehäuftes Auftreten von Intersexgonaden während der Differenzierungsphase hinweisen könnte.

3.3. Überwachungsprogramm (siehe Kapitel C)

Brienzlig von den Laichplätzen Merligen und Faulensee zeigten signifikant mehr Gonadenveränderungen, als die Felchen-Morphe Albock von den Standorten Schifflätti und Gwatt. Abnormale Gonaden waren bei den Männchen bei jedem Standort höher als bei den Weibchen. Im Gegensatz zu den unterschiedlichen Frequenzen der Gonadenveränderungen bei Männchen der Brienzlig- und Albock-Morphen, waren keine signifikanten

Laichplatzunterschiede im hepatischen VTG mRNA Level und im Testosteron- und 11-Ketotestosteron-Spiegel nachweisbar. Zudem wurden keine signifikanten Unterschiede des VTG mRNA- und Sexualsteroid-Level zwischen männlichen Fischen mit oder ohne Gonadenveränderungen aufgedeckt. Die Absenz von signifikanten Unterschieden in den VTG mRNA- und Sexualsteroid-Level zwischen Laichplätzen mit hoher (Merligen, Faulensee) und Laichplätzen mit tiefer Frequenz der Gonadenveränderungen (Schifflätti, Gwatt) einerseits und zwischen Fischen mit oder ohne Gonadenveränderungen an jedem Standort andererseits, weist darauf hin, dass Gonadenveränderungen in Thunerseefelchen nicht durch eine östrogene Exposition induziert wurden.

Intersexgonaden wurden in Felchen bei allen Laichplätzen mit einer sehr tiefen Häufigkeit gefunden, ausser am Standort Merligen, bei dem die Intersexhäufigkeit mit 15% Ovotestis in männlichen Felchen überraschend hoch war. Es waren jedoch alles milde Formen von Zwittergonaden, mit einzelnen oder wenigen Oozyten verteilt in normalem Hodengewebe. Aufgrund der Tatsache, dass weder VTG- noch Steroidmessungen Hinweise auf eine östrogene Exposition der Felchen vom Standort Merligen gaben, kommen wir zum Schluss, dass keine Anzeichen einer östrogenen Exposition, trotz der erhöhten Intersex-Häufigkeit, bestehen.

4. CONCLUSIO

Abschliessend können zu den eingangs gestellten Fragen folgende Antworten gegeben werden:

1. Die Ergebnisse des E2 Expositionsexperimentes zeigen, dass Exposition von Felchen an östrogen wirksame Stoffe nicht zur Ausbildung der Thunersee-charakteristischen makroskopischen Gonadenveränderungen führt. Die E2 Exposition hat jedoch Veränderungen wie sie von anderen Fischarten als typisch für eine östrogene Belastung beschrieben wurden, insbesondere die Induktion von Intersex und VTG zur Folge.
2. Der Ontogenieversuch zeigte, dass die morphologischen Gonadenveränderungen bereits früh in der Entwicklung auftreten, d.h., sie werden in der Entwicklung mit angelegt und nicht nachträglich in der bereits differenzierten Gonade induziert. Einschnürungen und Asymmetrien kamen erstmals im ersten oder zweiten Lebensjahr vor. Aplasien und Unterteilungen hingegen wurden erst im dritten Lebensjahr beobachtet.

3. Das Überwachungsprogramm erbrachte mittels der drei Biomarker - VTG mRNA, Sexualsteroide, Intersex - keine Hinweise auf eine endokrine Exposition von Felchen im Thunersee.

Zusammengenommen machen es diese Ergebnisse unwahrscheinlich, dass die im Thunersee auftretenden Gonadenveränderungen der Felchen durch EDCs ausgelöst sind. Die Frage nach der Ursache der Veränderungen muss daher noch weiterverfolgt werden. Weitere laufende Studien klären mögliche genetische Probleme (mittels Kreuzungsversuchen), Einflüsse der Nahrung, sowie chemische Stoffe, welchen die Felchen möglicherweise ausgesetzt waren, ab.

5. LITERATUR

Baroiller JF, Guiguen Y, Fostier A (1999) Endocrine and environmental aspects of sex differentiation in fish. Cellular and Molecular Life Sciences 55:910-931

Bernet D, Wahli T, Kueng C, Segner H (2004) Frequent and unexplained gonadal abnormalities in whitefish (central alpine *Coregonus sp*.) from an alpine oligotrophic lake in Switzerland. Diseases of Aquatic Organisms 61:137-148

Bittner D, Bernet D, Wahli T, Segner H, Küng C, Largiader CR (2007) How normal is abnormal? – Discriminating between deformations and natural variation in gonad morphology of European whitefish *Coregonus lavaretus* (L.) from Swiss lakes. Jounal of Fish Biology, eingereicht.

Blazer VS (2002) Histopathological assessment of gonadal tissue in wild fishes. Fish Physiology and Biochemistry 26:85-101

Goto R, Abe Y, Masai K, Yamaha E, Adachi S, Yamauchi K (1999) Effects of environmental factors on sex differentiation in goldfish (*Carassius auratus*). In: Norberg B, Kjesbu OS, Taranger GL, Andersson E, Stefansson SO (eds) Reproductive physiology of fish. Proceedings of the 6th International Symposium, Bergen

Hunter JR, Macewicz BJ (1995) Rates of atresia in the ovary of captive and wild northern anchovy (*Engraulis mordax*). Fish Bulletin. California Department of Fish and Game 83:119-136

Jobling S, Nolan M, Tyler CR, Brighty G, Sumpter JP (1998) Widespread sexual disruption in wild fish. Environmental Science & Technology 32:2498-2506

Jobling S, Tyler CR (2003) Endocrine disruption, parasites and pollutants in wild freshwater fish. Parasitology 126:S103-S108

Kime DE (1995) The effects of pollution on reproduction in fish. Reviews in Fish Biology and Fisheries 5:52-96

Kinnison MT, Unwin MJ, Jara F (2000) Macroscopic intersexuality in salmonid fishes. New Zealand Journal of Marine and Freshwater Research 34:125-134

Kitano T, Takamune K, Kobayashi T, Nagahama Y, Abe SI (1999) Suppression of P450 aromatase gene expression in sex-reversed males produced by rearing genetically female larvae at a high water temperature during a period of sex differentiation in the Japanese flounder (*Paralichthys olivaceus*). Journal of Molecular Endocrinology 23:167-176

Leino RL, Jensen KM, Ankley GT (2005) Gonadal histology and characteristic histopathology associated with endocrine disruption in the adult fathead minnow (*Pimephales promelas*). Environmental Toxicology and Pharmacology 19: 85-98

Matozzo V, Gagné F, Marin MG, Ricciardi F, Blaise C (2007) Vitellogenin as a biomarker of exposure to estrogenic compounds in aquatic invertebrates: A review. Environment International Article. in press.

McMaster ME., van der Kraak GL, Portt CB, Munkittrick KR, Sibley PK, Smith IR, Dixon DG (1991) Changes in hepatic mixed-function oxidase, activity, plasma steroid levels, and age at maturity of a white sucker (*Catostomus commersoni*) population exposed to bleached kraft pulp mill effluent. Aquatic Toxicology 21: 199-218

Mikaelian I, de Lafontaine Y, Harshbarger JC, Lee LLJ, Martineau D (2002) Health of lake whitefish (*Coregonus clupeaformis*) with elevated tissue levels of environmental contaminants. Environmental Toxicology and Chemistry 21:532-541

Noaksson E, Tjarnlund U, Bosveld ATC, Balk L (2001) Evidence for endocrine disruption in perch (*Perca fluviatilis*) and roach (*Rutilus rutilus*) in a remote Swedish lake in the vicinity of a public refuse dump. Toxicology and Applied Pharmacology 174:160-176

Norrgren L, Bengtsson BE, Börjeson H (1994) Summary of the workshop “Reproduction Disturbances in Fish”. In: Norrgren L (ed) Report from the Uppsala workshop on reproduction disturbances in Fish. Swedish Environmental Protection Agency, Solna, p 7-11

Patino R, Davis KB, Schoore JE, Uguz C, Strussmann CA, Parker NC, Simco BA, Goudie CA (1996) Sex differentiation of channel catfish gonads: Normal development and effects of temperature. Journal of Experimental Zoology 276:209-218

Porte C, Janer G, Lorusso LC, Ortiz-Zarragoitia M, Cajaraville MP, Fossi MC, Canesi L (2006) Endocrine disruptors in marine organisms: Approaches and perspectives. Comparative Biochemistry and Physiology C-Toxicology & Pharmacology 143:303-315

Segner H, Caroll K, Fenske M, Janssen CR, Maack G, Pascoe D, Schafers C, Vandenbergh GF, Watts M, Wenzel A (2003) Identification of endocrine-disrupting effects in aquatic vertebrates and invertebrates: report from the European IDEA project. Ecotoxicology and Environmental Safety 54:302-314

Sumpter JP, Jobling S (1995) Vitellogenesis as a biomarker for estrogenic contamination of the aquatic environment. Environmental Health Perspectives 7:173-8.

Van der Ven L, van den Brandhof EJ, Vos JH, Wester PW (2007) Effects of the estrogen agonist 17β-etradiol and antagonist tamoxifen in a partial life-cycle assay with zebrafish (*Danio rerio*). Environmental Toxicology and Chemistry 26: 92-99

Wiklund T, Lounasheimo L, Lom J, Bylund G (1996) Gonadal impairment in roach *Rutilus rutilus* from Finnish coastal areas of the northern Baltic sea. Diseases of Aquatic Organisms 26:163-171

KAPITEL A

Long term laboratory estrogen (E2) exposure of whitefish (central alpine *Coregonus* sp.) induces intersex but not the Lake Thun-typical gonad malformations

Kipfer S, Segner H., Wenger M, Wahli T, Bernet D

Long term laboratory estrogen (E2) exposure of whitefish (central alpine *Coregonus* sp.) induces intersex but not the Lake Thun-typical gonad malformations

Kipfer S, Segner H., Wenger M, Wahli T, Bernet D

Centre for Fish and Wildlife Health, University of Bern, Laenggass-Strasse 122, Post-Box 8466, CH-3001 Bern, Switzerland

Corresponding author: Tel.: +41 31 631 24 65

fax: +41 31 631 24 61

email: helmut.segner@itpa.unibe.ch

Running title: E2 exposure of whitefish

ABSTRACT

A high prevalence of morphological gonad variations has been observed in whitefish (*Coregonus* sp.) from Lake Thun (Switzerland). To clarify the role of endocrine disruption as a possible cause of the gonad alterations, whitefish were reared in a long-term laboartory experiment under exposure to 17β-estradiol (E2). Fish were fed from start-feeding until 3 years of age with a daily ratio of 0 (control), 0.5 or 50 µg E2 kg^{-1} d^{-1}. The long-term E2 administration resulted in a time- and concentration-dependent increase of prevalence and intensity of intersex gonads, i.e. gonads that macroscopically appeared as either testis or ovary but microscopically contained both male and female germ cells. Four types of intersex could be distinguished. The Lake Thun typical macroscopical gonad alterations were not induced by the E2 administration. The oral administration of E2 resulted in endocrine disruptive effects: a concentration dependent shift towards females, a reduced condition factor and gonad growth with a delayed maturation of the germ cells, and elevated liver vitellogenin mRNA levels.

Chronically E2-exposed whitefish displayed responses typical of fish exposed to estrogen-active substances, but not the Lake Thun characteristic macroscopical gonad deformations. The results do not provide evidence that estrogen active compounds play a role as etiology of the gonad malformations.

Keywords: estrogen, whitefish, Coregonid, gonad, sex differentiation, intersex, reproduction, morphology, vitellogenin

INTRODUCTION

In the year 2000 commercial fishermen reported the occurrence of morphologically altered gonads in whitefish (*Coregonus* sp.) from Lake Thun (Switzerland). An initial survey showed that 35% of the examined whitefish in Lake Thun had gonad alterations deviating from normal morphology (Bernet et al. 2004). Macroscopic and microscopic examinations revealed several types of alterations: adhesions/fusions to the peritoneal wall and the lateral trunk musculature, asymmetry, aplasia/atrophy, compartmentations, constrictions and intersex. More recent investigations have shown that some of the morphological gonad alteration types are also present in coregonids of two neighboring lakes. Constricted and asymmetrical gonads were revealed in comparable frequencies in whitefish from Lake Brienz and Lake Biel. This indicates that these traits represent to a large extent natural variation in gonad morphology of whitefish. However, the situation in Lake Thun is unique with respect to the enhanced overall prevalence of malformations and the significantly higher occurrence of four types of gonad alterations, i.e. intersex gonads, compartmentations, fusions and aplasia/atrophy (Bittner et al. 2007). Until now, the causes of the gonad alterations are not clear. As Lake Thun water is used as the source of drinking water for about 400'000 inhabitants of Switzerland, there is public concern that toxic chemicals may be involved. In addition, whitefish is a frequently eaten fish. With respect to human health and the health of the coregonid populations it is important to clarify the causes of the gonad alterations.

Variations of gonad morphology of fish have been reported from a number of studies worldwide (Norrgren et al. 1994, Hunter & Macewicz 1995, Kinnison et al. 2000, Blazer 2002, Mikaelian et al. 2002). In fact, morphology and differentiation of the gonads of fish are known to be susceptible to a variety of environmental factors such as temperature (Patino et al. 1996, Baroiller et al. 1999, Goto et al. 1999, Kitano et al. 1999), parasites (Wiklund et al. 1996, Jobling & Tyler 2003) or chemical substances (Kime 1995, Jobling et al. 1998, Noaksson et al. 2001). One environmental condition that has been found repeatedly to be causative to gonad alterations of fish is exposure to endocrine-disrupting compounds (EDCs) (Segner et al. 2003, Porte et al. 2006, Matozzo et al. 2007). Among the endocrine-active substances, chemicals that act as estrogen-receptor ligands and activate estrogen signaling pathways have received the most attention. These compounds include industrial chemicals (so-called xenoestrogens; e.g., certain alkylphenols or bisphenol A), phytoestrogens, as well as natural and synthetic estrogens (Kavlock et al. 1996, Jobling & Tyler 2003, Sumpter & Johnson 2005). Both field and laboratory studies have shown that exposure of developing fish to estrogen-active compounds can induce alterations of gonad morphology, including the

development of hermaphroditic or intersex gonads, i.e. the presence of oocytes in testicular tissue (Gray & Metcalfe 1997, Gray et al. 1999, Seki et al. 2002, Palace et al. 2006).

The aim of the present study is to evaluate whether exposure of developing coregonids to estrogen-active compounds would induce the specific Lake Thun typical gonad malformations, i.e. intersex, gonad compartmentations and adhesions/fusions, and aplasia/atrophy. To this end we exposed whitefish to the natural estrogen, 17β-estradiol (E2) under laboratory conditions. A chronic exposure scenario reaching from start feeding up to 3 years of age was chosen, since that covers the period of gonad development in whitefish (Bernet unpublished).

The specific questions of the study were (a) whether long-term E2 exposure is able to induce gonad alterations in whitefish, and (b) whether the E2-induced alterations are identical or similar to those found in whitefish in Lake Thun. Fish and their gonads were macro- and microscopically examined. In addition, histopathological investigations on heart, kidney and liver were made as E2 induced pathologies have been described in other estrogen treated fish species as well (Folmar et al. 2001, Zaroogian et al. 2001, Palace et al. 2006, Zha et al. 2007). In order to assess the effectiveness of the dietary E2 administration, hepatic expression of vitellogenin (VTG) was measured, as this gene is under direct control of the estrogen receptor pathway.

MATERIALS AND METHODS

Experimental design

Adult Whitefish (central alpine *Coregonus* sp.) of the ecotype “Albock” from Lake Thun were artificially stripped. The fertilized eggs and early larvae were reared in spring water in the governmental hatchery Reutigen, Switzerland. At an age of 87 days post hatch, on May 19, 2005 the fish were transferred to the Centre for Fish and Wildlife Health, University of Bern, where they were divided into three groups with 145 fish each and adapted over one month in 220 l aquaria supplied by tap water. On June 25, 2005 (122 dph), the experimental treatments were started and maintained until October 10, 2007 (960 dph). One group served as control and received a commercial diet (feed type see below, Hokovit, Bützberg, Switzerland). The second group (hereafter called “low dose group” (LD)) was fed with the same diet but enriched with 0.05 mg 17β-estradiol (E2) kg^{-1} feed. Fish from the third group (“high dose group” (HD)) were fed 5 mg E2 kg^{-1} feed. All groups were fed at 1% body weight per day. This makes a daily intake rate of 0.5 µg kg^{-1} fish (LD group) and 50 µg kg^{-1} fish (HD

group), respectively. From 98 dph until 148 dph all fish were fed AgloNorse 1 (0.3-0.6 mm grain size, EWOS, Norway), until 220 dph they were fed AgloNorse 2 (0.6-1.0 mm grain size; EWOS, Norway) and until 390 dph they were fed Hokovit Silvercup Superstarter 500 (Hokovit, Bützberg, Switzerland). Thereafter until end of experiment (960 dph), the treatment groups received pellets of 1.2 mm size (Hokovit, Bützberg, Switzerland). Fish from the control group received until 493 dph equal pellets and until 960 dph they received pellets of 1.6 mm size (Hokovit, Bützberg, Switzerland).

Addition of E2 (Estradiol (2,4,16,16-D4, 95-97%); DLM-2487-0; Cambridge Isotope Laboratories, Inc., Andover, USA) to the diet was achieved by using the alcohol method of Guerreo (1975). In brief, a stock solution of E2 was generated (50 µg E2 ml^{-1} Ethanol); high dose: 10 g food with 1 ml stock solution dissolved in 9 ml Ethanol; low dose 10 g food with 0.01 ml stock solution dissolved in 9.99 ml Ethanol; control 10 g food dissolved in 10 ml Ethanol. The solutions were then dried for 24 h at a temperature of 70°C.

Water temperature was measured daily to estimate the day degrees. Monthly the biomass of each group was calculated and the diet portion (1% kg^{-1} fish weight) readjusted.

Sampling

Fish were sampled at 14, 42, 77, 347 and 838 days of E2 exposure, corresponding to 136, 164, 191, 469 and 960 dph, respectively. Fish were killed with an overdose of Tricaine Methanesulfonate, Finquel MS 222 (Argent Chemical Laboratories, Redmont, WA, USA), and afterwads measured and weighed. The condition index was calculated as CI = 100 * W L^{-3}, where W = body weight (g) and L = total length (cm). For histological investigations, fish up to a length of 7 cm were fixed *in toto* in 4% buffered formalin. In bigger fish, the gonads were dissected and macroscopically assessed for malformations according to the criteria of Bernet et al. (2004), i.e. for each individual the presence or absence of the following morphological traits was recorded: constriction, asymmetry, atrophy/aplasia, compartmentation, adhesion/fusion, and intersex. The gonads were preserved in buffered formalin. At the final sampling (838 days of exposure), the gonads were weighed for the calculation of the gonadosomatic index GSI = gonad weight / body weight * 100. Liver tissue was dissected and preserved in RNAlater (Ambion, Austin, TX, USA) for vitellogenin analysis.

Histology

Formalin fixed fish or gonads were paraffin-embedded, cut into 5 μm thick sections and stained with haematoxylin-eosin according to standard procedures. The histological staging of the germ cells during gonad differentiation followed the descriptions of of Patino & Redding (2000) and van Aerle et al. (2004) for fathead minnow, *Pimephales promelas*. Germ cells were classified into primordial germ cells (PGC) in juvenile fish, primary oocytes (PO), bouquet stage, chromatin-nucleolar stage (CN), peri-nucleolar stage (PN), balbiany body stage (BB), cortical alveolus stage (CA), the first occurrence of egg shells, vitellogenic (VO) and mature oocytes in female fish. In male fish, spermatogonia, spermatocytes, spermatides, spermatozoa, the occurrence of testis lobules, and the presence of the sperm duct in the testis strands were used for classification. Intersex gonads were classified in macroscopic and microscopic intersex. Macroscopic intersex gonads were further classified as “mosaic gonad type” (Kinnison et al. 2000), also termed as “multifocal distribution type” (Nolan et al. 2001), and “lobular gonad type” (Kinnison et al. 2000) or “focal distribution type” (Nolan et al. 2001). In mosaic intersex fish, ooyctes occur in testicular tissue or spermatogenic cells develop in ovarian tissue. The “lobular gonad type” is characterised by confined areas of ovarian and testicular tissue along a gonad strand, often separated by connective tissue. Microscopic intersex gonads were classified macroscopically as either testis or ovary but contained microscopically both male and female germ cells. Microscopic intersex types were further distinguished in type 1 to 4. Type 1 was composed of mainly male tissue with single oocytes and type 2 had ovary like lamellae structure of the male tissue. In type 3 the female parts were increased and in type 4 male germ cells were mainly replaced by female germ cells.

At the final sampling, germ cells of one section per individual from the HD group (n_{males} = 1; $n_{females}$ = 15), from the LD group (n_{males} = 3; $n_{females}$ = 5) and from the control group (n_{males} = 8; $n_{females}$ = 7) were quantified stereologically. To this end, micrographs were taken using the x 40 objective of the light microscope for testicular tissue and x 2.5 for ovarian tissue on randomly selected areas (Zeiss universal microscope with a 35-mm Nikon digital camera). A 9 field standardized grid with mesh lengths of 60 µm for testicular tissue and 909 µm for ovarian tissue was laid over every picture. Male germ cells and BB, CA, egg shell, VTG and atresia stage in the ovaries of four not adjacent fields were counted, including partially cut germ cells. The area of 4 fields was defined with 0.014 mm^2 for testis and 3.305 mm^2 for ovary sections.

Real-time RT-PCR for relative quantification of VTG mRNA gene expression

RNA preparation. Total RNA was extracted from liver tissue of whitefish using Trizol Reagent (Invitrogen, Basel, Switzerland) according to the manufacturer's protocol. The extracted RNA was resuspended in RNA storage solution (Invitrogen). To remove traces of contaminating DNA, the RNA samples were treated with DNase (Ambion) before RT-PCR analysis. The concentration of the purified RNA was measured at 260 and 280 nm using an NanoDrop ND-1000 UV-vis spectrophotometer (NanoDrop Technologies, Wilmington, DE, USA).

Reverse transcription. Syntheses of cDNA were carried out in a 50 μl reaction mixture containing RNase free water (Applied Biosytems, Forster City, CA, USA), buffer, 500 μg ml^{-1} random primers, 40 u μl^{-1} RNase inhibitor, 10 mMol dNTPs and 200 u μl^{-1} M-MLV reverse transcriptase (Promega, Madison, WI, USA). To this 42 μl reaction mixture, 1 μg RNA was added. The cDNA synthesis was performed in a thermocycler (PTC-200 DNA Engine, MJ Research, BioConcept, Allschwil, Switzerland) under the following conditions: 25°C for 10 min, 42°C for 1 h and 94°C for 10 min.

Primer and probes design for TaqMan real-time RT-PCR. Based on established vitellogenin mRNA sequences of *Onchorhynchus mykiss*, *Danio rerio*, *Cyprinus carpio* and *Fundulus heteroclitus,* primers for *Coregonus lavaretus* for conventional RT-PCR were designed. By using a one-step RT-PCR Kit (Quiagen, Hombrechtikon, Switzerland), the RT-PCR amplification of the target gene was performed, checked on a agarose gel and sequenced as described by (Burki et al. 2006). Based on the partial sequences of VTG as determined by sequencing, a primer and one internal fluorescent probe (Table 1) was designed using the primer express software (PE Biosystems, Foster City, CA, USA). The internal probes were labeled at the 5' end with the reporter dye 6-carboxyfluorescein and at the 3' end with the quencher dye 6-carboxytetramethyl-rhodamine (Burki et al. 2006).

VTG real-time RT-PCR. Triplicates of 25 μl reactions consisting of Master Mix (Applied Biosystems, Forster City, CA, USA), H2O, 2 μMol probe (Microsynth, Balgach, SG, Switzerland), 10 μMol of forward and reverse VTG-Primer (Microsynth) and 2 μl of cDNA template were combined using a 96-well plate. Real-time RT-PCRs were performed using a 7300 Real-Time PCR System (Applied Biosystems) in conjugation with 7300 SDS-software (Applied Biosystems). The thermal program used was as follows: Stage 1: 50°C for 2 min, stage 2: 95°C for 10 min and stage 3: 95°C for 15 min with 45 repetitions and the final stage 60°C for 1 min (point of data collection).

18s RNA was measured as reference gene according to the manufacturers protocol using a kit by Applied Biosystems.

Dilution curve of VTG mRNA. A dilution curve was generated by performing a two-step, real-time RT-PCR on a 10-fold dilution series of the total extracted RNA containing VTG mRNA. To estimate the amplification efficiency of VTG mRNA and 18s RNA, dilution curves (10-fold dilution steps) of total hepatic RNA were prepared from a positive control sample (liver of mature female). The Ct values of the various dilutions were determined by means of two-step real-time RT-PCR for VTG and 18s, respectively. Form these Ct values, the slope of the dilution curves was determined. The slope of the VTG mRNA dilution curve was compared to the slope of the 18s RNA dilution curve. In addition, the slope of the 18s RNA dilution curve was compared to the slope of 18s RNA as specified by the manufacturer (Applied Biosystems Application Note, part number 127AP05). Efficiency was not significantly different for all amplifications.

Data analysis. Transcript abundance of VTG was normalized to the abundance of 18s and reported as number of VTG copies / 1000 copies of 18s (Pfaffl 2001, Muller et al. 2002, Garcia-Reyero et al. 2004).

Statistical analysis

Differences in intersex frequency between the groups were analyzed using Fisher's Exact test. Group differences of both CI and GSI values, were determined by the Kruskal-Wallis Multiple comparison Z-value test. VTG values were log transformed and tested for normality. A pair wise comparisons of VTG values between groups, sample time and normality/abnormality of the gonads were performed using a GLM Two-way-ANOVA, where "treatment group" and "sampling date" or "gonad morphology" were categorical independent variables, followed by a Tukey-Kramer Multiple-Comparison Test. Homoscedasticity and normality of the residuals of this model were checked using a multiple regression model since it was not possible to make calculate the residuals with the GLM Two-way-ANOVA function of the used software. All statistical analyses were performed using NCSS 2001 (Number Cruncher Statistical Systems, Kaysville, USA).

RESULTS

Initially, we report whether E2 treatment induced the Lake Thun-typical morphological gonad alterations in the experimental fish. In a second part, we describe further parameters potentially affected by E2 exposure including sex ratio and vitellogenin levels.

Effects of chronic E2 exposure on the prevalence of Lake-Thun-typical gonad morphological alterations in whitefish.

Gonad alterations reported from whitefish from Lake Thun include adhesions/fusions, asymmetry, atrophy, compartmentations, constrictions and intersex, both macroscopical and microscopical (Bernet et al. 2004). In chronically E2 exposed fish from the experiment, atrophic, constricted and intersex gonads were detected (Table 2). Gonad atrophy and gonad constrictions were observed both in controls and E2-treated fish (Table 2). These two alterations did not show a dose-dependent response to E2 administration: Gonad atrophy was observed in 4.1% of the females from the control, in 5.2% in the LD and in 1.6% of the HD group. Males with atrophic gonad strands were only seen in the LD group (7.7%) (Table 2). Constrictions of the gonads were present in 9.6% of the control males and in 2.5% of the LD males. In HD treatment group constrictions were present only in females, with a prevalence of 1.6%. None of the other macroscopical gonad alterations observed in feral whitefish from Lake Thun were present (i.e. compartmentations, fusions or asymmetrical gonads).

The only gonad alteration that showed a clear and dose-dependent relation to E2 feeding in our experiment was intersex. Long-term feeding of developing coregonids with E2-enriched diets resulted in a significant and dose-dependent increase of the number of fish showing intersex gonads (Chi-Square test; n_c= 113; n_{LD} = 115; n_{HD}= 90; $p < 0.05$). Intersex gonads were only detectable histologically. No macroscopical intersex – as one of the eye-catching morphological traits in whitefish from Lake Thun – was observed. While in the control group 1% of the fish had intersex gonads, 6.7% of the fish in the LD group had intersex gonads, and in the HD group it was 20.5% (Table 2). The intersex gonads were all of the mosaic type, i.e. single oocytes or oocytes in clusters multifocally scattered throughout the testicular tissue. There was an age-dependent change in the morphologcial appearance of the intersex gonads: In whitefish younger than 800 dph, most intersex gonads appeared macroscopically as testis, and were also microscopically dominated by testicular structures, with only single oocytes dispersed in the tissue. In contrast, in fish older than 800 dph, the majority of the intersex gonads appeared macroscopically as ovaries and microscopically they were dominated by an increased number of female germ cells, which now often appeared in clusters within the remaining male germ cells. Thus, four types of intersex morphology could be distinguished (Fig.1): Type 1 showed mainly male tissue with normal lobular structure of the male segments and multifocally distributed, single oocytes. In type 2, the testicular tissue with spermatogonia and/or spermatocytes as germ cells, showed an ovary-like lamellar structure, with a few oocytes being localized single or in clusters. The male structures clearly

dominated over the female elements. In both types 1 and 2, the vast majority of the oocytes was in the perinucleolar, Balbiani body or cortical alveolar stage, i.e. in early stages of oocyte maturation. The presence of single oocytes caused only minimal disruption to the male gonad tissue. When clusters of oocytes were present, they displaced sperm cysts within the lobule but did not change the overall testicular structure. In type 3 of intersex gonads, the ratio between male and female germ cells was shifted towards the female germ cells. The gonad tissue showed a lamellar structure containing approximately equal proportions of intermingled clusters of either male or female germ cells. Usually, the male germ cell clusters contained one or two consecutive sperm cell maturation stages. The female germ cells were mostly in the Balbiani body and cortical alveolar stage. Due to the increased number and size, the female germ cells could locally displace the male cells within the gonad. Finally, in type 4, female germ cells occupied most parts of the gonad strand, with little space remaining for male tissue. The female germ cells of type 4 were in the perinucleolar, Balbiani body or cortical alveolar stage, but also in the VTG stage. In male parts mainly spermatocytes and spermatids occurred. In the HD group, an increase of both intersex prevalence and intensity with exposure time was revealed (Fig. 2). At 191 dph, the intersex frequency of HD fish was 20%, and at exposure end at 960 dph it increased to 30.6%. In the LD fish the intersex prevalence was 16.7% at 191 dph and declined to 6.7% at 960 dph. In control fish intersex was detected only in one fish at 469 dph (prevalence of 1.4%) (Fig. 2). The increasing intersex intensity was characterized by a shift of intersex type 1 to intersex type 4 (Fig. 2). Comparing the macroscopic appearance of the gonads that were microscopically classified as intersex the exposure time dependent feminization was also clearly distinguishable. At 469 dph 100% of the microscopic intersex were macroscopically assessed as testis, while at 960 dph 72.7% were macroscopic ovaries (Table 3).

Effects of chronic E2 exposure on sex ratio, condition indices, gonad maturation status, histopathology and VTG mRNA expression of whitefish.

In addition to the development of intersex gonads, a number of other endpoints responded to the E2 treatments: (1) sex ratio, (2) condition factor, (3) gonadosomatic index and gonad maturation status, (4) histopathology of liver, heart, kidney and gonads, and (5) VTG mRNA expression.

(1) Long-term exposure to E2 resulted in a dose-dependent shift of the sex ratio towards females. While in the control group 48% were females, the percentage of fish with female gonads was 55.8% in LD and 70.5% in HD (Table 2). Control and LD groups differed significantly from the HD group (Fisher's Exact Test; $p < 0.05$; $n_c = 102$; $n_{LD} = 104$; $n_{HD} = 88$), whereas LD was not significantly different to controls ($p > 0.05$).

(2) Both males and females of the control and LD treatments had significantly higher condition factors than fish of the HD group (Kruskal-Wallis Multiple Comparison Z-Value Test; $p < 0.05$; males: $z > 1.9$; $n_c = 8$; $n_{LD} = 3$; $n_{HD} = 1$; females: $z > 1.9$; $n_c = 7$; $n_{LD} = 5$; $n_{HD} = 16$) (Fig. 3). No significant differences were found between fish of the control and the LD treatment ($p > 0.05$).

(3) Females of the control and LD groups had a significantly higher GSI than females of the HD group (Kruskal-Wallis Multiple Comparison Z-Value Test; $p < 0.05$; $z > 1.9$; $n_c = 7$; $n_{LD} = 5$; $n_{HD} = 16$) (Fig. 4). The GSI of males from the control group tended to be higher than in the HD group, although the difference was not significant ($p > 0.05$; $z = 1.2$). A significant difference, however, was evident between the two E2 treatments, with LD males showing higher GSI than HD males (Kruskal-Wallis Multiple Comparison Z-Value Test; $p < 0.05$; $z > 1.9$; $n_c = 8$; $n_{LD} = 3$; $n_{HD} = 1$) (Fig. 4). The lower GSI of HD-exposed fish correlates with a delayed maturation status of the germ cells in both sexes (Fig. 5). At final sampling, after 838 days of exposure, ovaries of fish from the control and LD groups were characterized by the prominent presence of vitellogenic ooyctes, while ovaries from fish of the HD group were dominated by early oocyte stages, like the Balbiani and cortical alveolar stage, whereas the number of vitellogenic oocytes was low (Fig. 5). Further, while males of the control and LD groups had started with spermatozoa production in their testes at day 838 after start of exposure, no spermatozoa were present in testes of fish from the HD group which were composed mainly of spermatocytes and spermatids, together with a small number of spermatogonia (Fig. 5).

(4) In HD fish, a multifocal, slight to moderate accumulation of homogenous eosinophilic material was seen in the cytoplasm of the hepatocytes, as well as in the intercellular and vascular spaces of the liver tissue, in the cavity and in the coronary vessels of the heart, and in the glomerular loops and Bowman's space of the kidney (Fig. 6). Moreover, kidneys of fish from the HD group showed a moderate to severe fibroblastic proliferation of the walls of the Bowman's capsule (sclerotic glomeruli) as well as of blood vessel walls, and a moderate to severe thickening (classical wire-loop appearance), together with partial ruptures of the glomerular basement membranes and capsules. These histopathological alterations in the kidney are indicative of a chronic glomerulonephritis. In the LD group, histopathological changes were less strongly expressed and less frequent, for instance, thickening of the glomerular basement membranes in the kidney was slight and occurred in only 3.8% of the fish. No accumulation of homogenous eosinophilic material was observed in liver, heart and kidney of fish from the LD and control groups. Pathological changes beyond the altered sexual differentiation features described above occurred also in the gonads. Slightly more

than half of the fish of the HD group (59.1 %) showed an interstitial accumulation of homogenous eosinophilic material as well as a proliferation of fibroblasts in the arterial walls. In the LD group an accumulation of homogenous eosinophilic material was found in only 4.8% of the gonads and it was absent from the gonads of control fish. In all treatments the gonads of a few fish showed areas with slight to moderate inflammation with comparable prevalences (control: 16.7%; LD: 12.5%; HD: 17.0%), containing either neutrophilic granulocytes, eosinophilic granular cells or macrophages, or a mixture of these cells.

(5) Hepatic VTG mRNA levels were significantly induced in a dose-dependent manner by chronic E2 administration (Tukey-Kramer Multiple-Comparison Test; $p < 0.05$; $n_c = 21$; $n_{LD} = 19$; $n_{HD} = 23$; Fig. 7). Male fish in the control group had median VTG mRNA values of 0.1 copies / 1000 copies of 18s RNA. In the LD group the median value was 5.4 / 1000 copies of 18s RNA, and in HD fish 32’798 / 1000 copies of 18s RNA. In the LD group, hepatic VTG mRNA values of male fish were significantly increased over control values at day 347 of E2 exposure, but differed no longer at final sampling (838 days of exposure) (Fig.8). Hepatic VTG mRNA values in fish from the HD treatment group were significantly elevated over control values from the very first sampling onward. There was no significant change in the induced VTG levels in the course of the experiment, from the very first until final sampling. In female control fish, median VTG mRNA values were 0.4 copies / 1000 copies of 18s RNA. These values were only marginally higher than the male VTG values, because 73.7% of female fish were in the previtellogenic stadium. In the LD group the level was 27.5 / 1000 and in the HD group it was 26’696 / 1000. The time course of the hepatic VTG mRNA induction in females of the 3 treatment groups were nearly congruent with that of the males. However, at the final sampling point, females of the control and the LD group had VTG values corresponding to that of females from the HD treatment groups.

Within all three treatment groups, the VTG-levels of male fish with normal and deformed gonads (i.e. in our case atrophy and intersex) did not differ significantly (Tukey-Kramer Multiple-Comparison Test $p > 0.05$).

DISCUSSION

In the present study, whitefish were chronically exposed to E2 from 122 dph (startfeeding) to 960 dph (completion of morphological gonad differentiation and maturation), resulting in 838 days of exposure. While a number of long-term estrogenic exposure studies have been performed with fast developing small laboratory species, like fathead minnow (Lange et al. 2001), zebrafish (Nash et al. 2004, Fenske et al. 2005) and medaka (Seki et al. 2002),

chronic estrogenic exposures have been rarely performed with long-lived, seasonally spawning fish species. Rodgers-Gray (2001) exposed roach (*Rutilus rutilus*) from 50 dph to 200 dph (germ cell differentiation incomplete in some fish, presumptive males) to a graded concentration of effluents from sewage treatment plants. Liney (2006) used a similar exposure scenario with roach from fertilization to 300 dph (completed sexual differentiation). In both studies estrogen-exposed males developed feminized reproductive ducts, but no effects on germ cell differentiation were reported. Further, in whole lake experiments, pearl dace (*Margariscus margarita*) (Palace et al. 2006) and fathead minnow (*Pimephales promelas*) (Kidd et al. 2007) were chronically exposed to 17α-ethynylestradiol (EE2) what resulted in the manifestation of intersex gonads and altered oogenesis. The reason why long-lived wild fish species have been rarely used in prolonged exposure experiments may be related to the problems in their long-term rearing under laboratory conditions.

E2 exposure of developing whitefish resulted in physiological and pathological alterations as reported from other fish species exposed to estrogen-active compounds. Estrogen-dependent effects were clearly expressed in the HD group, but weak to absent in the LD group. Hepatic VTG mRNA levels showed a significant and concentration-dependent induction response to E2 administration. This finding confirms that the dietary E2 administration as used in the present study was effective. VTG induction is a well-established biomarker response of fish for estrogenic exposure of fish (Sumpter & Jobling 1995). Advantages of the VTG biomarker are that the induction response, which is mediated through the estrogen receptor, is sensitive, specific and rapid (Arukwe & Goksoyr 2003). At sampling 4 (347 days of exposure), VTG levels of male fish from the LD group were significantly higher compared to the control group, however, at the final sampling (838 days of exposure), the difference was no longer significant since VTG levels in control fish clearly increased from 347 to 838 days of exposure. This observation suggests that the LD treatment induced a precocious VTG expression in male fish. A low level of VTG expression in control males has been reported for several fish species and appears to be a normal background situation (Navas & Segner 2006). Females from the control group at termination of the experiment showed pronounced hepatic VTG mRNA expression reflecting their state of ovarian maturity. Hepatic VTG expression levels of females from the LD and HD group did not differ significantly from those of control females, i.e. the estrogenic exposure was not able to elevate hepatic VTG mRNA above levels as they occur naturally in maturing females.

A concentration-dependent increase in the prevalence of intersex gonads and an exposure-time dependent enhancement of the intensity of intersex manifestation was found. In the HD treatment group, up to 21% of the fish displayed intersex gonads. The available literature on

intersex induction in estrogen-exposed fish points to some level of species specificity of this endpoint. In zebra fish (*Danio rerio*), for instance, only very few intersex gonads were induced with EE2 exposure (5 ng l^{-1}) over a whole life cycle (Nash et al. 2004). In juvenile roach (*Rutilus rutilus*) exposure to estrogenic effluents resulted in the feminization of the gonad duct, but not in the development of intersex in terms of mixed germ cells (Rodgers-Gray et al. 2001). A new observation of the present study was the relation between intersex morphology and duration of exposure, as indicated from the time-dependent shift in intersex intensity (from type 1 to 4) and from the observation that during early development (191 dph), microscopical intersex occurred mainly in gonads appearing macroscopically as testes, while later in development (> 800 dph), microscopical intersex occurred predominantely in gonads appearing macroscopically as ovaries. We suppose that these fish are genotypically males that underwent an almost full sex reversal developing ovaries, except the presence of a few remnant male germ cells in the gonads. However, in the absence of a reliable method to determine the genotypical sex in whitefish, we cannot verify our assumption. Overall, however, intersex induction seems to be a dynamic process and occurs as an in-between stage from the phenotypical male to the phenotypical female gonad (Gray & Metcalfe 1997).

In the HD group fish displayed major histopathological changes in liver, heart, kidney and gonads. Histopathological lesions occurred after a prolonged E2 exposure, i.e. rupture of the renal glomeruli. This was also observed in Folmar et al. (2001). These pathologies are a consequence of the VTG-protein overload in the blood circulation by a continuous E2 feeding and may lead to kidney function failure and affect heart activity. Prominent accumulation of homogenous eosinophilic material occurred in fish from our study. We interpreted the large amounts of homogenous eosinophilic material deposited in the organs mentioned above as vitellogenin. In summer flounder (*Paralichthys dentatus*) the VTG deposits were identified by immunohistochemistry (Folmar et al. 2001). In other studies deposits of homogenous eosinophilic material were described, but not further identified, i.e. in summer flounder (*Paralichthys dentatus*) exposed to E2 (Zaroogian et al. 2001), in pearl dace (*Margariscus margarita*) exposed to synthetic estrogen (Palace et al. 2006) and in rare minnow (*Gobiocypris rarus*) exposed to ethynylestradiol and nonylphenol (Zha et al. 2007).

Male fish from the HD group had smaller GSI and parallel to that had less matured germ cells than fish from the other groups. These observations indicate that E2 in high doses reduces testis maturation and therefore also the GSI, and go in parallel with studies from Gimeno et al. (1998a, 1998b) and (Diniz et al. 2005). However, no differences in the GSI were found in roach (*Rutilus rutilus*) exposed to estrogen-active sewage treatment plant effluents (Rodgers-Gray et al. 2001). Fish of the control and LD treatment groups had

significantly higher condition factors than fish of the HD group. The CF of HD fish was significantly reduced, due to both reduced weight and length. The reduced length may be explained with the IGF-E2 crosstalk, while the reduced weight may be a consequence of less disposable energy which is used for E2 metabolization or it could be a sign of a toxicological effect of the E2 adminsitartion to the fish (Ashfield et al. 1998).

The chronic E2 exposure resulted in a dose-dependent shift of the sex ratio towards females. Increased number of fish with phenotypically female gonads as a result of developmental estrogenic exposures were also reported from other fish species, e.g. Japanese medaka (*Oryzias latipes*) (Gray & Metcalfe 1997), tilapia (*Oreochromis niloticus*) (Shved et al. 2008) and white sucker (*Catostomus commersonii*) (Vajda et al. 2008). In gonochorists such as whitefish, sex steroids act as organizers of the sex differentiation during a sensitive window of the gonad development (Yamamoto 1969, Devlin & Nagahama 2002). It is this organizational role of sex steroids in gonad differentiation that makes the developing gonad sensitive to environmental endocrine-disrupting compounds and can switch genetic males into phenotypical females (Segner et al. 2006).

In contrast to the effects discussed above which appear to be typical for E2-exposed fish, the gonad alterations reported from feral whitefish of Lake Thun were not induced by E2 administration. The E2-exposed fish displayed frequencies of the different morphological gonad variations between 0% (compartmentation, fusion, asymmetry) and 5.8% (atrophy). Neither a concentration dependency nor significant between-group differences were observed for the Lake Thun-typical gonad alterations. In feral whitefish from Lake Thun, the frequencies of the various morphological gonad alterations are clearly higher than in our experimental groups, with values between 3% (constrictions), 4% (atrophy/aplasia; asymmetry), 5% (fusions) and 11% (compartmentations) (Bernet et al., 2004). The only exception was the formation of microscopic intersex gonads. In the laboratory E2 experiment, the prevalance of microscopical intersex gonads was significantly higher (20.5%) than in the lake (1.1 % on average, Bernet, unpublished).

In conclusion, long term exposure of European whitefish, *Coregonus lavaretus*, to E2 during the whole period from gonad differentiation until gonad maturity resulted in typical estrogen-disruptive effects like (i) elevated VTG mRNA levels, (ii) the formation of microscopic intersex gonads, (iii) accumulation of vitellogenin in the liver, heart, kidney and gonads, (iv) a reduced condition factor and gonad growth with delayed maturation of the germ cells, and (v) concentration-dependent shift of the sex ratio towards females. Importantly, the developmental estrogen exposure did not induce the gonad morphological features as described to be characteristic for Lake Thun coregonids. Therefore, we conclude that a

causative role of estrogenic compounds in the morphological gonad alterations of Lake Thun whitefish is rather unlikely. This, however, does not exclude a role of the Lake Thun environment in the induction of the malformations. Further studies are ongoing to examine the role of Lake Thun water, food, and sediment in causing this enigmatic biological phenomenon.

Acknowledgement. This study was funded by the NRP 50 “Endocrine Disruptors: Relevance to Humans, Animals and Ecosystems”. We are grateful to B. Mueller for her help in maintaining the fish.

TABLES

Table 1. Primers and probe for the TaqMan real-time reverse transcriptase-polymerase chain reaction of *Coregonus lavaretus* vitellogenin (VTG)

Primer/Probe[a]	Sequence (5' -> 3')	PRC fragment length (bp)
VTG TaqMan fw	ATC AAG AAG ACA CAG AAC GTC TAT GAG (27 bp)	177
VTG TaqMan rv	CTG ATC ACA TAG TGG GTC TTG CA (23 bp)	
VTG TaqMan probe	CCC TGA GCT CCA GCC TCC TGC A (22 bp)	

[a]fw = forward; rv = reverse; bp = base pairs

Table 2. Observed gonad deviation types and sex ratios of whitefish from the control, low dose (LD), and high dose (HD) treatment group, stratified by sex (M=males; F=females, IS=intersex). Values shown are number of fish (N), frequency (*f*) and 95% confidence intervals (95% CI).

		Control group				Low dose group				High dose group			
		M	**F**	**IS**	**Total**	**M**	**F**	**IS**	**Total**	**M**	**F**	**IS**	**Total**
Atrophy	**N**	**0**	**2**		**2**	**3**	**3**		**6**	**0**	**1**		**1**
	f	*0*	*4.1*		*2.0*	*7.7*	*5.2*		*5.8*	*0.0*	*1.6*		*1.1*
	95% CI		0.5-14.0		0.2-6.9	1.6-20.9	1.1-14.4		2.1-12.1	0.0-0.0	0.0-8.7		0.0-6.2
Intersex	**N**			**1**	**1**			**7**	**7**			**18**	**18**
	f			*100.0*	*1.0*			*100.0*	*6.7*			*100.0*	*20.5*
	95% CI				0.0-5.3				2.7-13.4				12.6-30.4
Compartmentation	**N**	**0**	**0**		**0**	**0**	**0**		**0**	**0**	**0**		**0**
	f	*0*	*0*		*0*	*0*	*0*		*0*	*0*	*0*		*0*
	95% CI												
Fusion	**N**	**0**	**0**		**0**	**0**	**0**		**0**	**0**	**0**		**0**
	f	*0*	*0*		*0*	*0*	*0*		*0*	*0*	*0*		*0*
	95% CI												
Constriction	**N**	**5**	**0**		**5**	**1**	**0**		**1**	**0**	**1**		**1**
	f	*9.6*	*0*		*4.9*	*2.6*	*0*		*1.0*	*0*	*1.6*		*1.1*
	95% CI	3.2-21.0			1.6-11.1	0.1-13.5			0.0-5.2		0.0-8.7		0.0-6.2
Asymmetry	**N**	**0**	**0**		**0**	**0**	**0**		**0**	**0**	**0**		**0**
	f	*0*	*0*		*0*	*0*	*0*		*0*	*0*	*0*		*0*
	95% CI												
Sex ratio and Sample Size	**N**	**52**	**49**	**1**	**102**	**39**	**58**	**7**	**104**	**8**	**62**	**18**	**88**
	f	*51.0*	*48.0*	*1.0*	*100.0*	*37.5*	*55.8*	*6.7*	*100.0*	*9.1*	*70.5*	*20.5*	*100.0*
	95% CI	40.9-61.0	38.0-58.2	0.0-5.3		28.2-47.5	45.7-65.5	2.7-13.4		4.0-17.1	59.8-79.7	12.6-30.4	

Table 3. Microscopically classified intersex gonads compared with the macroscopic appearance of the gonads in the high dose treatment group. M=males, F=females, IS=intersex, ?=macroscopically not distinguishable. Values shown are number of fish (N) and frequency %.

		Macroscopic appearance			
	Age (dph)	**M % (N)**	**F % (N)**	**IS % (N)**	**? % (N)**
Microscopically classified as IS	191	(0)	(0)	(0)	*100.0* (1)
	469	*100.0* (7)	(0)	(0)	(0)
	960	*18.2* (2)	*72.7* (8)	(0)	*9.1* (1)

FIGURE CAPTIONS

Fig. 1 Various mosaic intersex gonads (Type 1 to 4) from the HD group. **a)** Type 1: Gonad section from a 661 dph old fish (20x). Balbiani body (arrowhead) and cortical alveolus stage oocytes (asterisk) are multifocally embedded from the border towards the center of the strand. The testicular tissue shows normal male lobular structure containing spermatocytes (short arrows) and spermatides (long arrows). **b)** Type 2: Gonad section from a 787 dph old fish (10x). Note the ovary like lamellar structure (long arrows) containing spermatocytes (short arrows) and the Balbiani body (arrowhead) and cortical alveolus stage (asterisk) oocytes multifocally distributed at the border of the gonad strand. **c)** Type 3: Gonad section from a 801 dph old fish (10x). The lamellar structured strand (inlay; 2.5x) contains mostly Balbiani body (arrowheads) and cortical alveolus stage oocytes (asterisks) that are surrounded by multifocal confluent clusters of spermatogonia and spermatocytes (both short arrows). **d)** Type 4: Gonad section from a 960 dph old fish (40x). Located between Balbiani body (arrowhead) and cortical alveolus stage oocytes (asterisks) are multifocal distributed nests containing spermatocytes (short arrow) and spermatides (long arrow). Overview (inlay; 10x).

Fig. 2 Frequency of different intersex types at the five consecutive sampling points. Intersex frequencies are given for the control group (a), for the LD group (b) and the HD group (c). The sampled fish number is indicated on the top x-axis.

Fig. 3 Condition factor (CF) in male and female whitefish from the control, low dose (LD) and high dose (HD) treatment group. Values shown are means ± S.E.

Fig. 4 Gonadosomatic index (GSI) in male (a) and female (b) whitefish from the control, low dose (LD) and high dose (HD) treatment groups at the final sampling (838 days of exposure). Every dot represents a value of a single fish.

Fig. 5 Germ cell numbers in males (a) and females (b) from the control, low dose (LD) and high dose (HD) treatment group. Values shown are means ± S.E.

Fig. 6 Organ sections from whitefish of the HD group. **a) Kidney section** (10x). Note fibroblastic proliferation of the Bowman's capsule walls (arrowhead) (sclerotic glomeruli) and vessel walls (arrows), **b) Kidney section** (40x), higher magnification of a glomeruli. Note thickening of the Bowman's capsule wall (arrowhead) and of the glomerular basement membranes (classical wire-loop appearance) with accumulation of homogenous eosinophilic material in the loops (arrowhead) and in the Bowman's space (asterisk). **c) and d) Heart sections** (40x). **c)** Accumulation of homogenous eosinophilic material in the heart cavity (asterisk) and **d)** in the coronary vessels (asterisk) is observable. **e) and f) Liver sections** (40x). **e)** Note vacuolar accumulation of homogenous eosinophilic material in the hepatocytes (arrows) and **f)** intravascular deposit of eosinophilic material (asterisk) with marked thickening of cholangiar and vascular walls.

Fig. 7 Hepatic vitellogenin (VTG) mRNA levels in males from the high dose (HD), low dose (LD) and control treatment groups, with normal and abnormal (atrophy and intersex) gonads. As a reference, the VTG values of females from the control group from the final sampling (838 days of exposure) are presented at the most right position. Values shown are median (bar symbol), 25th – 75th percentiles (box), and minimum-maximum (viscars).

Fig. 8 Hepatic vitellogenin (VTG) mRNA levels in male (upper figure) and female (lower figure) whitefish from the high dose (HD), low dose (LD) and control treatment group at the different samplings, except for the first sampling (14 days of exposure) due to insufficient amount of liver tissue. Values shown are means ± SE. The number at every point indicates sample size. Values with different lower case letters are significantly different (GLM Two-Way ANOVA with a Tukey- Kramer Multiple-Comparison Test; $P < 0.05$)

FIGURES

Fig. 1

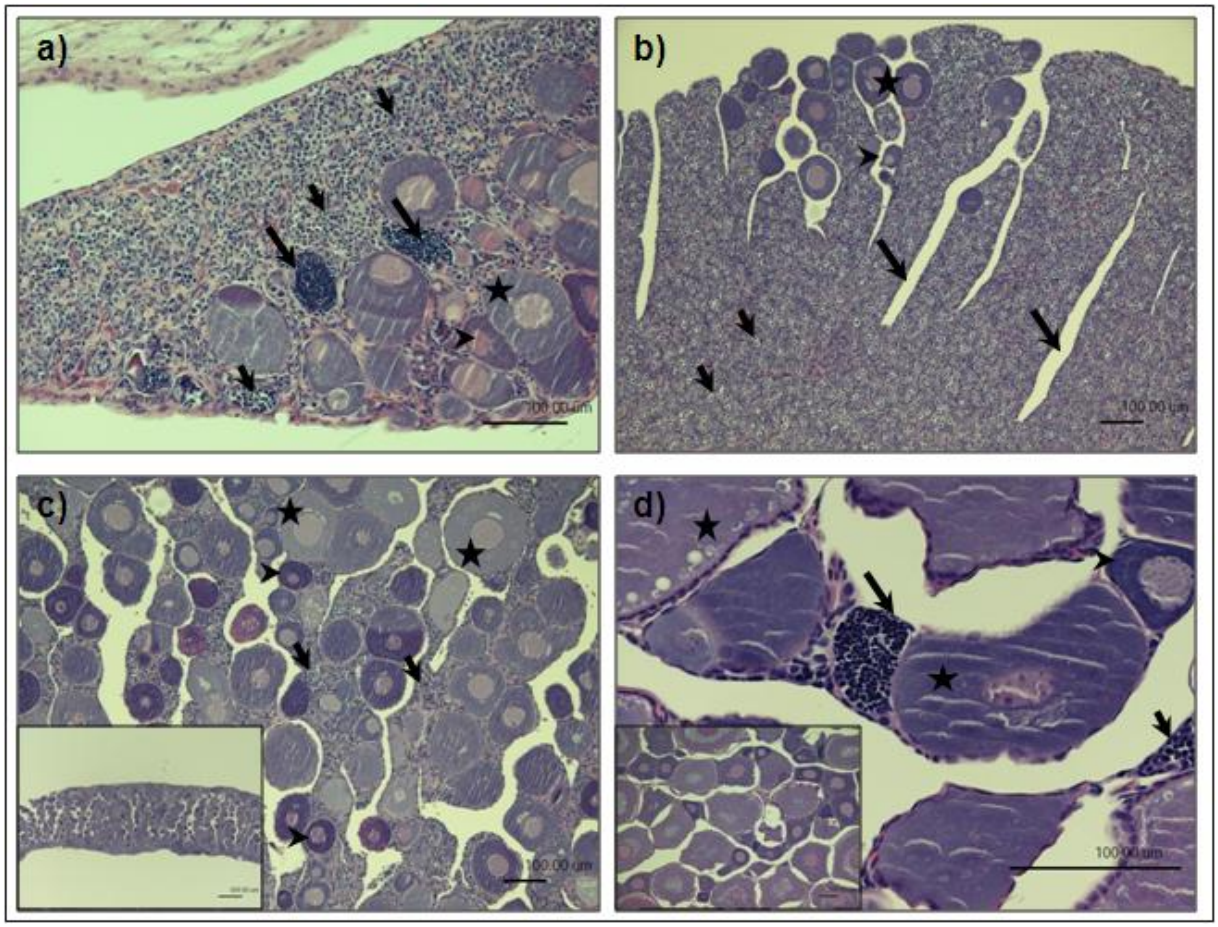

Fig. 2

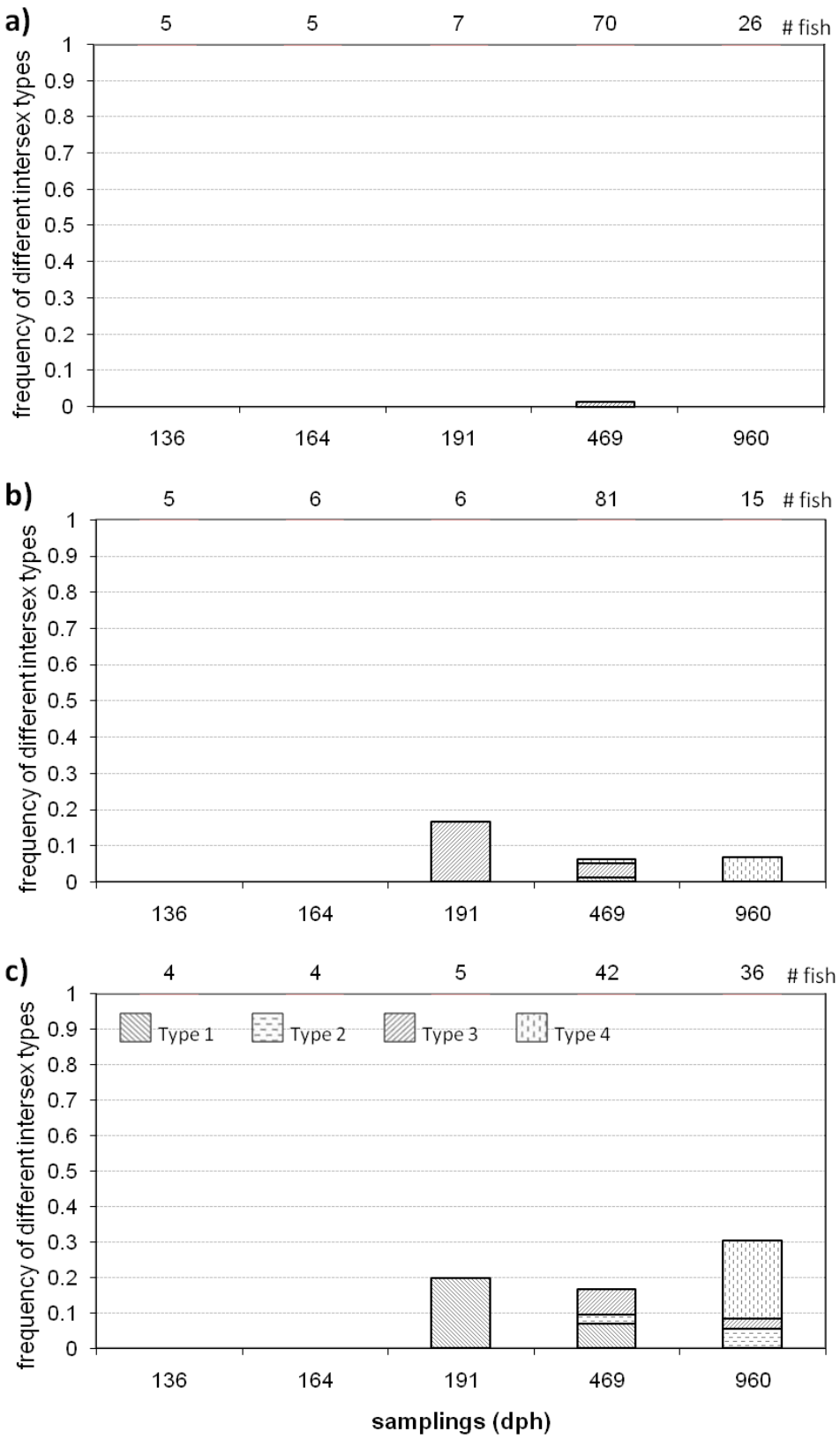
a)
5
5
7
70
26
fish
frequency of different intersex types
1
0.9
0.8
0.7
0.6
0.5
0.4
0.3
0.2
0.1
0
136
164
191
469
960
b)
5
6
6
81
15
fish
frequency of different intersex types
1
0.9
0.8
0.7
0.6
0.5
0.4
0.3
0.2
0.1
0
136
164
191
469
960
c)
4
4
5
42
36
fish
Type 1
Type 2
Type 3
Type 4
frequency of different intersex types
1
0.9
0.8
0.7
0.6
0.5
0.4
0.3
0.2
0.1
0
136
164
191
469
960
samplings (dph)

Fig. 3

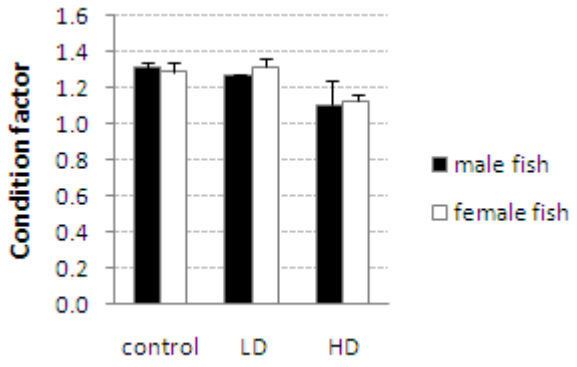
Condition factor
1.6
1.4
1.2
1.0
0.8
0.6
0.4
0.2
0.0
control
LD
HD
male fish
female fish

Fig. 4

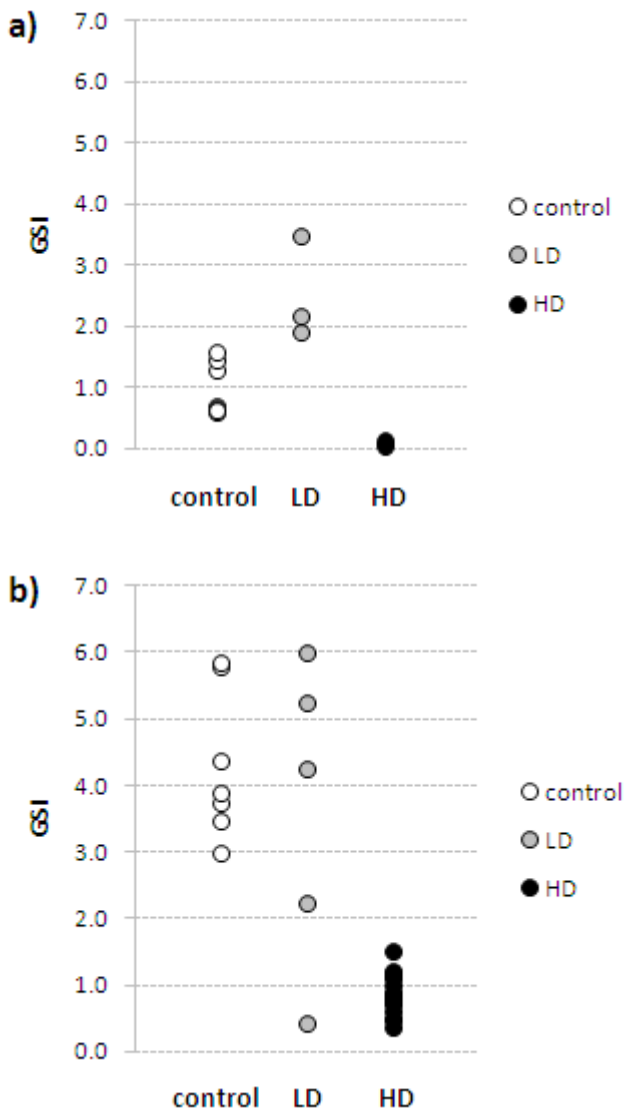
a)
7.0
6.0
5.0
4.0
3.0
2.0
1.0
0.0
GSI
control
LD
HD
control
LD
HD
b)
7.0
6.0
5.0
4.0
3.0
2.0
1.0
0.0
GSI
control
LD
HD
control
LD
HD

Fig. 5

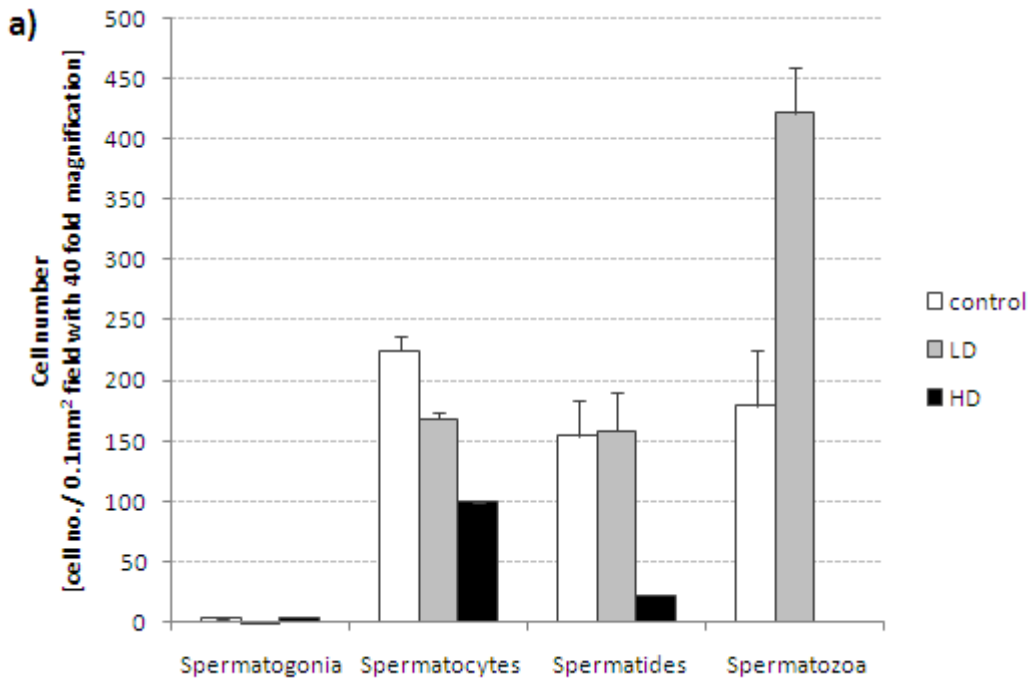
a)
Cell number
[cell no./0.1mm² field with 40 fold magnification]
500
450
400
350
300
250
200
150
100
50
0
Spermatogonia
Spermatocytes
Spermatides
Spermatozoa
control
LD
HD

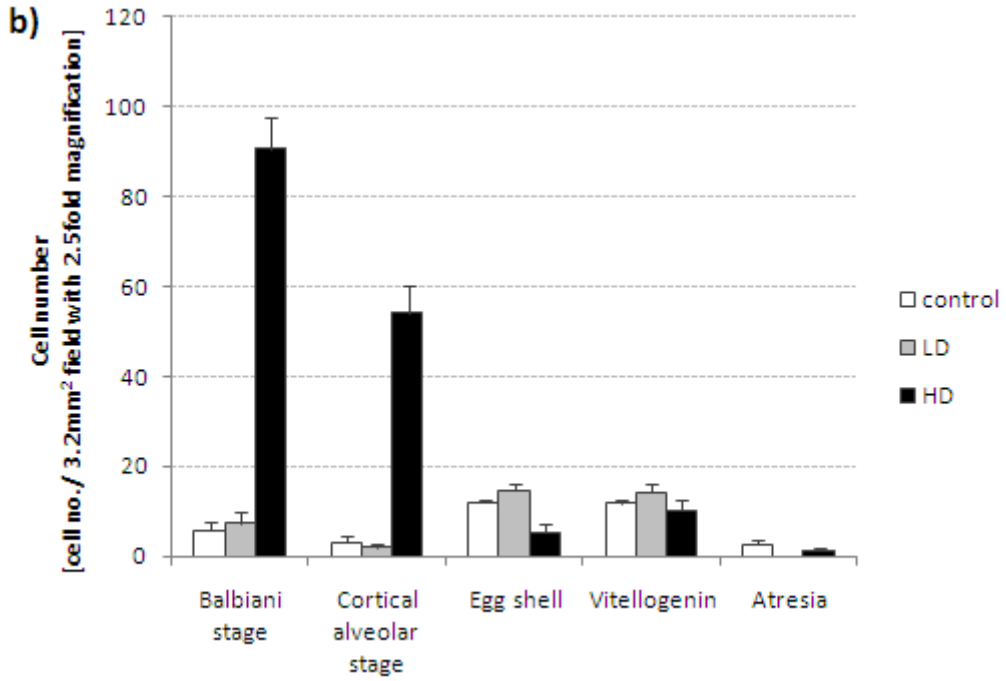
b)
Cell number
[cell no./3.2mm² field with 2.5fold magnification]
120
100
80
60
40
20
0
Balbiani stage
Cortical alveolar stage
Egg shell
Vitellogenin
Atresia
control
LD
HD

Fig. 6

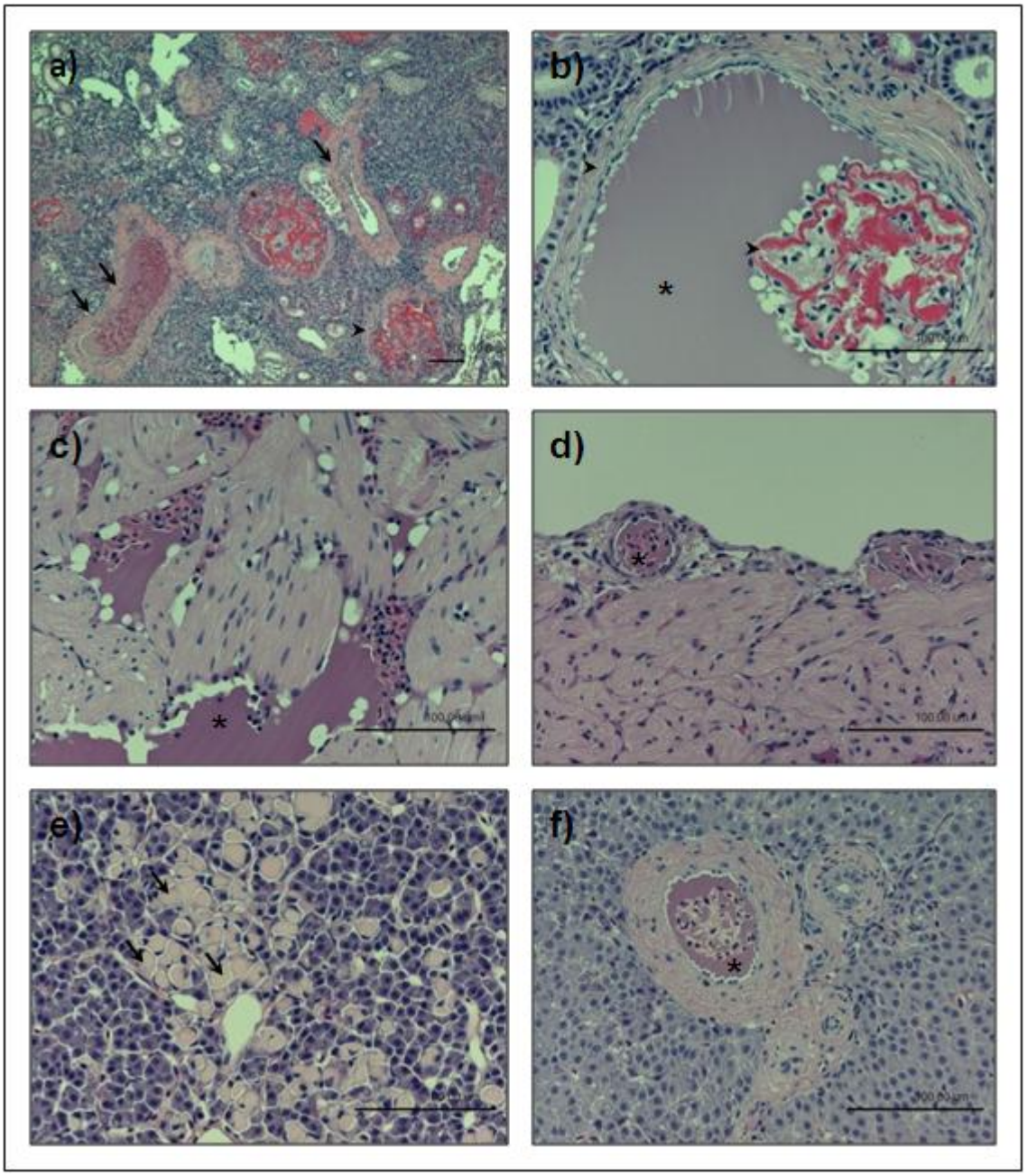

Fig. 7

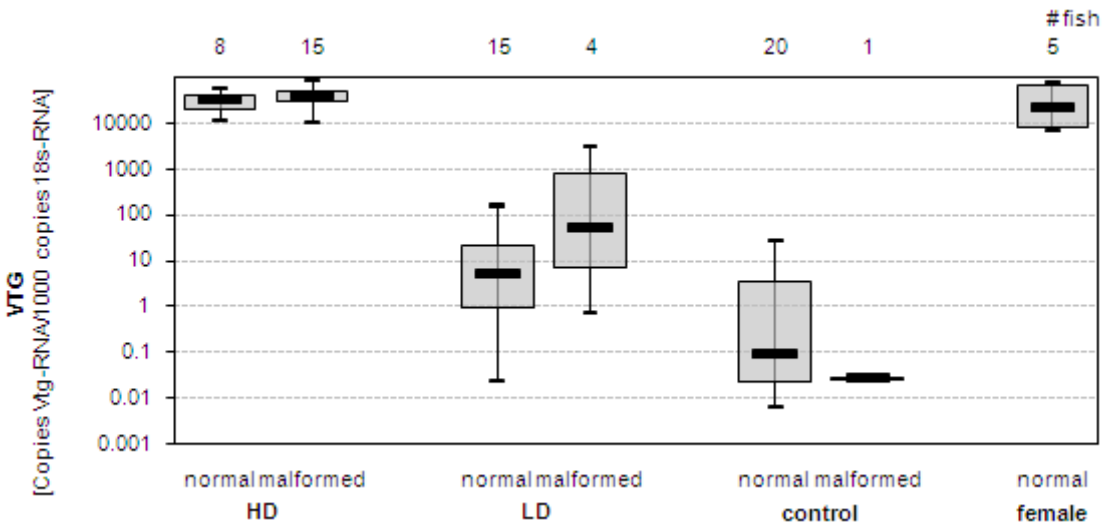
#fish
8
15
15
4
20
1
5
VTG
[Copies Vtg-RNA/1000 copies 18s-RNA]
10000
1000
100
10
1
0.1
0.01
0.001
normal
malformed
normal
malformed
normal
malformed
normal
HD
LD
control
female

Fig. 8

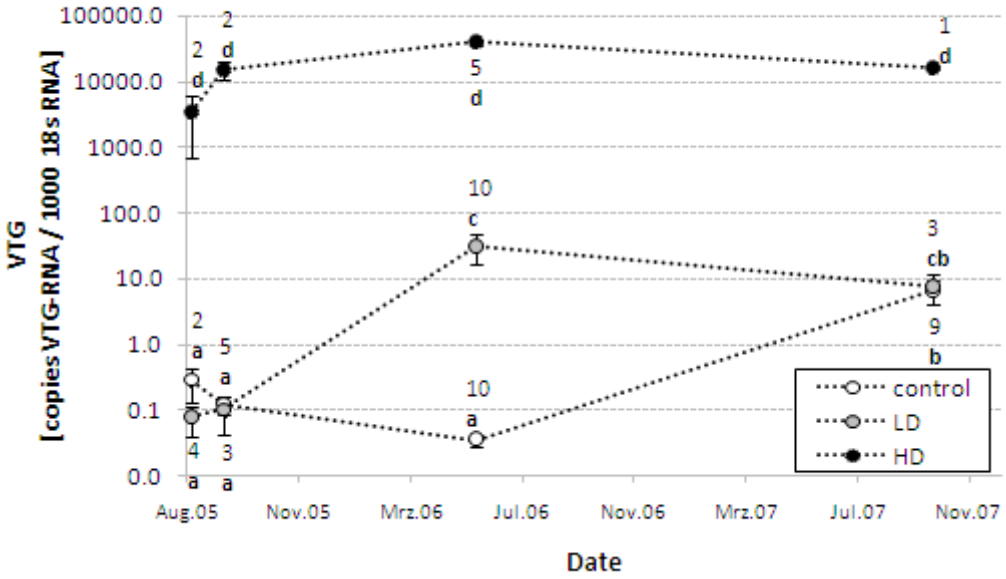
VTG
[copies VTG-RNA / 1000 18s RNA]
100000.0
10000.0
1000.0
100.0
10.0
1.0
0.1
0.0
Aug.05
Nov.05
Mrz.06
Jul.06
Nov.06
Mrz.07
Jul.07
Nov.07
Date
control
LD
HD

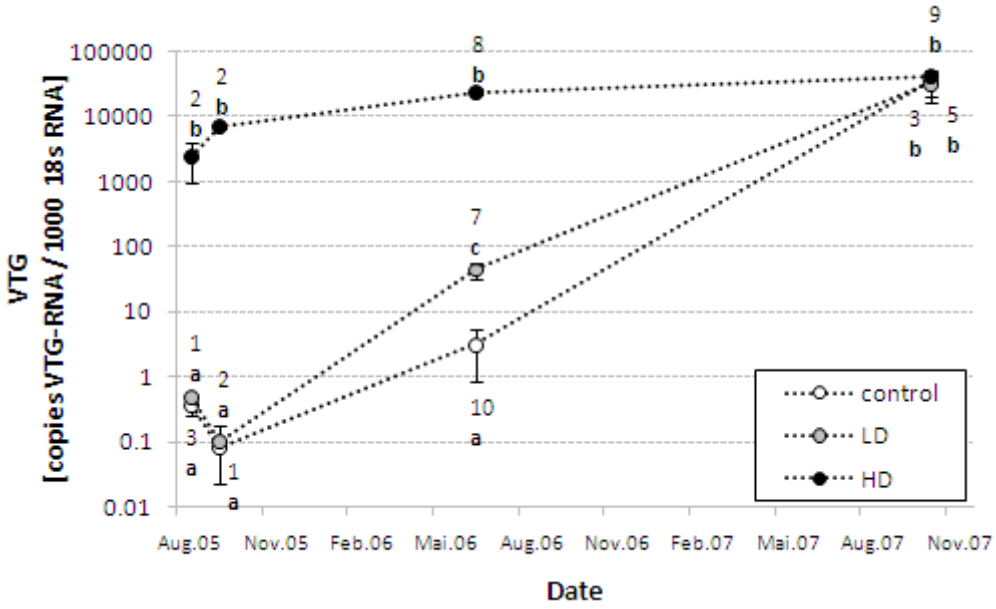
VTG
[copies VTG-RNA / 1000 18s RNA]
100000
10000
1000
100
10
1
0.1
0.01
Aug.05
Nov.05
Feb.06
Mai.06
Aug.06
Nov.06
Feb.07
Mai.07
Aug.07
Nov.07
Date
control
LD
HD

LITERATURE CITED

Arukwe A, Goksoyr A (2003) Eggshell and egg yolk proteins in fish: hepatic proteins for the next generation: oogenetic, population, and evolutionary implications of endocrine disruption. Comparative Hepatology 2:1-21

Ashfield LA, Pottinger TG, Sumpter JP (1998) Exposure of female juvenile rainbow trout to alkylphenolic compounds results in modifications to growth and ovosomatic index. Environmental Toxicology and Chemistry 17:679-686

Baroiller JF, Guiguen Y, Fostier A (1999) Endocrine and environmental aspects of sex differentiation in fish. Cellular and Molecular Life Sciences 55:910-931

Bernet D, Wahli T, Kueng C, Segner H (2004) Frequent and unexplained gonadal abnormalities in whitefish (central alpine Coregonus sp.) from an alpine oligotrophic lake in Switzerland. Diseases of Aquatic Organisms 61:137-148

Bittner D, Bernet D, Wahli T, Segner H, Küng C, Largaider CR (2007) How normal is abnormal? - Discriminating between deformations and natural variation in gonad morphology of European whitefish *Coregonus lavaretus* from Swiss lakes. Journal of Fish Biology submitted

Blazer VS (2002) Histopathological assessment of gonadal tissue in wild fishes. Fish Physiology and Biochemistry 26:85-101

Burki R, Vermeirssen ELM, Korner O, Joris C, Burkhardt-Holm P, Segner H (2006) Assessment of estrogenic exposure in brown trout (Salmo trutta) in a Swiss midland river: Integrated analysis of passive samplers, wild and caged fish, and vitellogenin mRNA and protein. Environmental Toxicology and Chemistry 25:2077-2086

Devlin RH, Nagahama Y (2002) Sex determination and sex differentiation in fish: an overview of genetic, physiological, and environmental influences. Aquaculture 208:191-364

Diniz MS, Peres I, Magalhaes-Antoine I, Falla J, Pihan JC (2005) Estrogenic effects in crucian carp (Carassius carassius) exposed to treated sewage effluent. Ecotoxicology and Environmental Safety 62:427-435

Fenske M, Maack G, Schafers C, Segner H (2005) An environmentally relevant concentration of estrogen induces arrest of male gonad development in zebrafish, Danio rerio. Environmental Toxicology and Chemistry 24:1088-1098

Folmar LC, Gardner GR, Schreibman MP, Magliulo-Cepriano L, Mills LJ, Zaroogian G, Gutjahr-Gobell R, Haebler R, Horowitz DB, Denslow ND (2001) Vitellogenin-induced pathology in male summer flounder (Paralichthys dentatus). Aquatic Toxicology 51:431-441

Garcia-Reyero N, Raldua D, Quiros L, Llaveria G, Cerda J, Barcelo D, Grimalt JO, Pina B (2004) Use of vitellogenin mRNA as a biomarker for endocrine disruption in feral and cultured fish. Analytical and Bioanalytical Chemistry 378:670-675

Gimeno S, Komen H, Gerritsen AGM, Bowmer T (1998a) Feminisation of young males of the common carp, Cyprinus carpio, exposed to 4-tert-pentylphenol during sexual differentiation. Aquatic Toxicology 43:77-92

Gimeno S, Komen H, Jobling S, Sumpter J, Bowmer T (1998b) Demasculinisation of sexually mature male common carp, Cyprinus carpio, exposed to 4-tert-pentylphenol during spermatogenesis. Aquatic Toxicology 43:93-109

Goto R, Abe Y, Masai K, Yamaha E, Adachi S, Yamauchi K (1999) Effects of environmental factors on sex differentiation in goldfish (Carassius auratus). In: Norberg B, Kjesbu OS, Taranger GL, Andersson E, Stefansson SO (eds) Reproductive physiology of fish. Proceedings of the 6th International Symposium, Bergen

Gray MA, Metcalfe CD (1997) Induction of testis-ova in Japanese medaka (Oryzias latipes) exposed to p-nonylphenol. Environmental Toxicology and Chemistry 16:1082-1086

Gray MA, Niimi AJ, Metcalfe CD (1999) Factors affecting the development of testis-ova in medaka, Oryzias latipes, exposed to octylphenol. Environmental Toxicology and Chemistry 18:1835-1842

Guerreo RD (1975) Use of androgens for the production of all-male Tilapia *Aurea steindachner*. Transactions of the American Fisheries Society 104:342-348

Hunter JR, Macewicz BJ (1995) Rates of atresia in the ovary of captive and wild northern anchovy (Engraulis mordax). Fish Bulletin. California Department of Fish and Game 83:119-136

Jobling S, Nolan M, Tyler CR, Brighty G, Sumpter JP (1998) Widespread sexual disruption in wild fish. Environmental Science & Technology 32:2498-2506

Jobling S, Tyler CR (2003) Endocrine disruption, parasites and pollutants in wild freshwater fish. Parasitology 126:S103-S108

Kavlock RJ, Daston GP, DeRosa C, FennerCrisp P, Gray LE, Kaattari S, Lucier G, Luster M, Mac MJ, Maczka C, Miller R, Moore J, Rolland R, Scott G, Sheehan DM, Sinks T, Tilson HA (1996) Research needs for the risk assessment of health and environmental effects of endocrine disruptors: A report of the US EPA-sponsored workshop. Environmental Health Perspectives 104:715-740

Kidd KA, Blanchfield PJ, Mills KH, Palace VP, Evans RE, Lazorchak JM, Flick RW (2007) Collapse of a fish population after exposure to a synthetic estrogen. Proceedings of the National Academy of Sciences of the United States of America 104:8897-8901

Kime DE (1995) The effects of pollution on reproduction in fish. Reviews in Fish Biology and Fisheries 5:52-96

Kinnison MT, Unwin MJ, Jara F (2000) Macroscopic intersexuality in salmonid fishes. New Zealand Journal of Marine and Freshwater Research 34:125-134

Kitano T, Takamune K, Kobayashi T, Nagahama Y, Abe SI (1999) Suppression of P450 aromatase gene expression in sex-reversed males produced by rearing genetically female larvae at a high water temperature during a period of sex differentiation in the Japanese flounder (Paralichthys olivaceus). Journal of Molecular Endocrinology 23:167-176

Lange R, Hutchinson TH, Croudace CP, Siegmund F, Schweinfurth H, Hampe P, Panter GH, Sumpter JP (2001) Effects of the synthetic estrogen 17 alpha-ethinylestradiol on the life-cycle of the fathead minnow (Pimephales promelas). Environmental Toxicology and Chemistry 20:1216-1227

Liney KE, Hagger JA, Tyler CR, Depledge MH, Galloway TS, Jobling S (2006) Health effects in fish of long-term exposure to effluents from wastewater treatment works. Environmental Health Perspectives 114:81-89

Matozzo V, Gagné F, Marin MG, Ricciardi F, Blaise C (2007) Vitellogenin as a biomarker of exposure to estrogenic compounds in aquatic invertebrates: A review. Environment International Article. in press.

Mikaelian I, de Lafontaine Y, Harshbarger JC, Lee LLJ, Martineau D (2002) Health of lake whitefish (Coregonus clupeaformis) with elevated tissue levels of environmental contaminants. Environmental Toxicology and Chemistry 21:532-541

Muller PY, Janovjak H, Miserez AR, Dobbie Z (2002) Processing of gene expression data generated by quantitative real-time RT-PCR. Biotechniques 32:1372-+

Nash JP, Kime DE, Van der Ven LTM, Wester PW, Brion F, Maack G, Stahlschmidt-Allner P, Tyler CR (2004) Long-term exposure to environmental concentrations of the pharmaceutical ethynylestradiol causes reproductive failure in fish. Environmental Health Perspectives 112:1725-1733

Navas JM, Segner H (2006) Vitellogenin synthesis in primary cultures of fish liver cells as endpoint for in vitro screening of the (anti) estrogenic activity of chemical substances. Aquatic Toxicology 80:1-22

Noaksson E, Tjarnlund U, Bosveld ATC, Balk L (2001) Evidence for endocrine disruption in perch (Perca fluviatilis) and roach (Rutilus rutilus) in a remote Swedish lake in the vicinity of a public refuse dump. Toxicology and Applied Pharmacology 174:160-176

Nolan M, Jobling S, Brighty G, Sumpter JP, Tyler CR (2001) A histological description of intersexuality in the roach. Journal of Fish Biology 58:160-176

Norrgren L, Bengtsson BE, Börjeson H (1994) Summary of the workshop “Reproduction Disturbances in Fish”. In: Norrgren L (ed) Report from the Uppsala workshop on reproduction disturbances in Fish. Swedish Environmental Protection Agency, Solna, p 7-11

Palace VP, Wautier KG, Evans RE, Blanchfield PJ, Mills KH, Chalanchuk SM, Godard D, McMaster ME, Tetreault GR, Peters LE, Vandenbyllaardt L, Kidd KA (2006) Biochemical and histopathological effects in pearl dace (Margariscus margarita) chronically exposed to a synthetic estrogen in a whole lake experiment. Environmental Toxicology and Chemistry 25:1114-1125

Patino R, Davis KB, Schoore JE, Uguz C, Strussmann CA, Parker NC, Simco BA, Goudie CA (1996) Sex differentiation of channel catfish gonads: Normal development and effects of temperature. Journal of Experimental Zoology 276:209-218

Patino R, Redding J (2000) Microscopical functional anatomy: Reproductive systems. In: Ostrander GK (ed) Handbook of Experimental Animals, The Laboratory Fish Academic Press, London, p 489-500

Pfaffl MW (2001) A new mathematical model for relative quantification in real-time RT-PCR. Nucleic Acids Research 29

Porte C, Janer G, Lorusso LC, Ortiz-Zarragoitia M, Cajaraville MP, Fossi MC, Canesi L (2006) Endocrine disruptors in marine organisms: Approaches and perspectives. Comparative Biochemistry and Physiology C-Toxicology & Pharmacology 143:303-315

Rodgers-Gray TP, Jobling S, Kelly C, Morris S, Brighty G, Waldock MJ, Sumpter JP, Tyler CR (2001) Exposure of juvenile roach (Rutilus rutilus) to treated sewage effluent induces dose-dependent and persistent disruption in gonadal duct development. Environmental Science & Technology 35:462-470

Segner H, Caroll K, Fenske M, Janssen CR, Maack G, Pascoe D, Schafers C, Vandenbergh GF, Watts M, Wenzel A (2003) Identification of endocrine-disrupting effects in aquatic vertebrates and invertebrates: report from the European IDEA project. Ecotoxicology and Environmental Safety 54:302-314

Segner H, Eppler E, Reinecke M (2006) The impact of environmental hormonally active substances on the endocrine and immune systems of fish. In: Reinecke M, Zaccone G, Kapoor BG (eds) Fish endocrinology, Vol 2, New Hampshire, p 809-865

Seki M, Yokota H, Matsubara H, Tsuruda Y, Maeda N, Tadokoro H, Kobayashi K (2002) Effect of ethinylestradiol on the reproduction and induction of vitellogenin and testis-ova in medaka (Oryzias latipes). Environmental Toxicology and Chemistry 21:1692-1698

Shved N, Berishvili G, Baroiller JF, Segner H, Reinecke M (2008) Environmentally relevant concentrations of 17alpha-ethinylestradiol (EE2) interfere with the growth hormone (GH)/insulin-like growth factor (IGF)-I system in developing bony fish. Toxicological Sciences in press

Sumpter JP, Jobling S (1995) Vitellogenesis as a biomarker for estrogenic contamination of the aquatic environment. Environmental Health Perspectives 103:173-178

Sumpter JP, Johnson AC (2005) Lessons from endocrine disruption and their application to other issues concerning trace organics in the aquatic environment. Environmental Science & Technology 39:4321-4332

Vajda AM, Barber LB, Gray JL, Lopez EM, Woodling JD, Norris DO (2008) Reproductive disruption in fish downstream from an Estrogenic wastewater effluent. Environmental Science & Technology 42:3407-3414

van Aerle R, Runnalls TJ, Tyler CR (2004) Ontogeny of gonadal sex development relative to growth in fathead minnow. Journal of Fish Biology 64:355-369

Wiklund T, Lounasheimo L, Lom J, Bylund G (1996) Gonadal impairment in roach Rutilus rutilus from Finnish coastal areas of the northern Baltic sea. Diseases of Aquatic Organisms 26:163-171

Yamamoto T (1969) Sex differentiation. In: Hoar WS, Randall DJ (eds) Fish Physiology, Vol 3. Academic, New York, p 117-175

Zaroogian G, Gardner G, Horowitz DB, Gutjahr-Gobell R, Haebler R, Mills L (2001) Effect of 17 beta-estradiol, o,p '-DDT, octylphenol and p,p '-DDE on gonadal development and liver and kidney pathology in juvenile male summer flounder (Paralichthys dentatus). Aquatic Toxicology 54:101-112

Zha JM, Wang ZJ, Wang N, Ingersoll C (2007) Histological alternation and vitellogenin induction in adult rare minnow (Gobiocypris rarus) after exposure to ethynylestradiol and nonylphenol. Chemosphere 66:488-495

KAPITEL B

Ontogeny of sex differentiation in whitefish with emphasis on morphology deviating from normality

Daniel Bernet, Thomas Wahli, Sibylle Kipfer, Michael Wenger, Helmut Segner

ONTOGENY OF SEX DIFFERENTIATION IN WHITEFISH WITH EMAPHASIS ON MORPHOLOGY DEVIATING FROM NORMALITY

Daniel Bernet, Thomas Wahli, Sibylle Kipfer, Michael Wenger, Helmut Segner

Centre for Fish and Wildlife Health, University of Bern, Laenggass-Strasse 122, Post-Box 8466, CH-3001 Bern, Switzerland

Corresponding author: Tel.: +41 31 631 24 65

fax: +41 31 631 24 61

email: daniel.bernet@itpa.unibe.ch

Running title: Sex differentiation in whitefish

ABSTRACT

In Lake Thun, Switzerland, a significant number of whitefish (*Coregonus lavaretus* s.l.) with gonad morphologies deviating from a normal arrangement was found in the resident population. The temporal onset during gonad development is not known so far. Thus we aimed at (a) examining whether the gonad alterations develop during or after gonad differentiation, and (b) characterising for the first time the entire ontogenetic gonadal development in an European whitefish species from hatching until maturity. For this, whitefish were reared under controlled conditions at two independent locations with distinct water sources and temperature regimes (Lake Thun water with temperatures between 5°C and 22°C, Spring water with constant water temperatures of 8-9°C).

Gonad development in the Spring water group was clearly delayed in respect to the age, but advanced in respect to fish size, and in accordance with the Lake Thun water group in respect to degree-days. Undifferentiated gonad anlagen were first seen at 65 days post hatch (dph), at a body length of 2 cm, and 491 day-degrees (d°C). Ovarian differentiation (starting from 1734 to 1820 d°C) preceded testicular differentiation (starting from 1989 - 3673 d°C). Once started, the testicular differentiation was continuous without “resting phases” as observed for ovarian differentiation between the cortical alveolar stage and the appearance of vitellogenic oocytes. The first males and females with mature germ cells were recognised synchronistically at 8163 - 8356 d°C.

Morphological gonad deviations became manifest during the gonad differentiation process. Constrictions and asymmetries, developed for the first time in the first (0+) or second (1+) year-of-life, at a body length of 13-18 cm. Aplasia and compartmentation were recorded in the third (2+) year-of-life at a body length of 16-18 cm. We observed in both groups a fairly high frequency of 8-9% intersex fish during the gonadal sex differentiation. At presence there is no evidence for the presence of exogenic endocrine active substances. Thus, we suppose to have evidence for a naturally increased mosaic intersex condition in whitefish during the ontogenetic gonadal differentiation process.

Key words: whitefish, Coregonid, gonad, ontogeny, sex differentiation, intersex, reproduction, morphology

INTRODUCTION

Several cases of fish populations with altered gonad morphology have been recorded in recent years (Ruby and Cairns, 1983; Wicklund et al., 1996; Demska-Zakes & Mamcarz, 1996; Fitzsimons and Cairns, 2000; Simpson et al., 2000; Rodgers-Gray et al., 2001; Kinnison et al, 2001; Mikaelian et al., 2002; Harrod & Griffiths, 2005). Also in Lake Thun, Switzerland, the resident population of whitefish (*Coregonus lavaretus* s.l.) is displaying a high frequency of 35% of fish with morphological gonad deviations from what is considered as normal (Bernet et al., 2004). These deviations attracted attention for the first time in the year 2000, and consisted of a variety of different macro- and microscopical variations in gonad morphology including adhesions/fusions of the gonads to the peritoneal wall and the musculature, asymmetry, atrophy and aplasia, compartmentations, constrictions, simultaneous hermaphroditism and intersex condition (Bernet et al., 2004). The proximal cause(s) of these morphological variations are not known yet. A extensive surveillance of whitefish populations in Lake Thun and two neighbour lakes over several years provided epidemiological criteria to distinguish between normal and aberrant gonad morphologies (Bittner et al., submitted). From the variation types described above only compartmentation, gonadal fusions to the peritoneal wall, intersex and aplasia turned out to be specific for Lake Thun, because these types were present at significantly higher prevalences in whitefish from Lake Thun than from neighbouring lakes. The frequency of abnormal gonads was influenced by factors such as sex, fish morph, spawning site and age. Fish with deformed gonads were observed in all age classes from $\geq$ 2 years. Due to limitations of gillnetting in the lake, it is difficult to sample representative numbers of fish younger than 2 years of age. Therefore, we currently have no information whether gonad deformations are present in whitefish younger than 2 years, and when the gonad alterations develop during ontogeny.

The aim of the present study was to examine whether the morphological deviations of whitefish from Lake Thun develop in parallel to gonad differentiation, or whether they are induced after completion of gonad differentiation. This knowledge is important to better understand the aetiology of the gonadal aberrations. A drawback is that gonad ontogeny of whitefish has not been described to date. Therefore, we additionally wanted to document the succession of sexual differentiation. We therefore reared whitefish from Lake Thun under controlled conditions and sampled them on a regularly basis from hatching until maturity at 3 years of age.

MATERIAL AND METHODS

Fish maintenance

In December 2002, mature whitefish (*Coregonus lavaretus* s.l.) were caught in Lake Thun on their spawning grounds by bottom gillnets. Eggs from females were stripped, pooled and semen from several males was added. The eggs were incubated in a Zuger jar supplied by water from Lake Thun. After hatch in February 2003, the larvae were kept in a circular 2000-l fibreglass tank supplied with Lake Thun water (hereafter called “Lake Thun water group”) and fed a combination of zooplankton from Lake Thun and dry food (in the first months AgloNorse Nr.1 and Nr.2 (EWOS AS, Bergen, Norway) and thereafter Silvercup 500 to 503 (Hokovit, Bützberg, Switzerland)). Fish were reared until the first specimens reached maturity in July 2005. Water temperature followed seasonal variation with minimum values of 4°C in February 2005 and a maximum of 22°C in August 2003 (Fig.1).

We ran a second rearing experiment to examine to what extent gonad development varies with rearing conditions. Eggs of whitefish collected from Lake Thun in December 2004 were incubated and hatched fish reared in a governmental fish farm near Lake Thun. The facility is supplied with spring water emerging at the bottom of a mountain slope at a constant temperature of 8-9°C (hereafter referred to as spring water group). After hatching, the larvae were transferred into a circular 2000-l fibreglass tank supplied by spring water and fed exclusively dry food (AgloNorse Nr.1 and Nr.2 (EWOS AS, Bergen, Norway) in the first months and thereafter Silvercup 500 to 503 (Hokovit, Bützberg, Switzerland)). Fish were maintained until October 2007.

In ectotherms, physiological processes that determine growth and development are directly influenced by temperature (i.e. Atkinson, 1994). In this respect, gonadal sex differentiation of fish varies with water temperature (i.e. Krol et al., 2003). Thus, numerical age (in days post-hatch [dph]) is not an appropriate unit to compare gonadal development between individuals reared at different water temperatures. Therefore, we describe in the present study gonad development not only in terms of numerical age, but additionally in terms of degree-days (d°C) as a sum of the mean daily water temperatures (Neuheimer & Taggart, 2007), to account for the temperature influence.

Sample collection

Fish from Lake Thun water group were sampled weekly in the first five months after hatching, and subsequently once a month during the following five months. During the second and

third year of life, fish were sampled once every second month in the first half of the year and monthly from July to December, respectively.

Fish sampling in the spring water group started when fish were 169 days old and were supposed to have launched ovarian differentiation. Samples were taken monthly until the completion of the first year, and thereafter the sampling scheme of the Lake Thun water group was applied.

At every sampling, 15 to 20 fish were euthanized with an overdose of Finquel (Argent Chemical Laboratories, Redmont, USA). Fish up to a length of 7 cm were fixed *in toto*. Larger fish were first opened ventrally before fixation in 4% buffered formalin. As soon as the gonads reached an adequate size in bigger fish (about >12 cm body length), they were excised and preserved in buffered formalin.

Fixed fish ≤ 7cm were cut longitudinally and embedded in paraffin. In larger fish fixed *in toto*, the gonads were removed before embedding. All excised gonads were morphologically assessed according to Bernet *et al.* (2004), i.e. for each individual the presence or absence of the following morphological states was recorded: constriction, asymmetry, atrophy/aplasia, compartmentation, adhesion/fusion, and intersex. From all paraffin blocs sections of 3 – 5 um were mounted on slides, stained with Mayer's haematoxylin and eosin and examined by light microscopy. The histological assessment of the germ cells during the gonadal differentiation followed the descriptions of Patino & Redding (2000) and van Aerle et al. (2004). Fish were assessed as functionally „mature", as soon as ripe germ cells, i.e. ovulated oocytes or milt, was released.

Furthermore, gonad histology was assessed in 275 wild whitefish (age: mean 2.9 years; min: 1 year; max. 7 years) from Lake Thun to reveal the prevalence of mosaic type intersex gonads in the free living whitefish population from Lake Thun. To this end, 25 fish were collected every month from hauls of commercial fishermen, except in November when fishing was suspended due to the spawning season. Gonads from these fish were excised, macroscopically assessed according the morphological states described by Bernet et al. (2004) and fixed in 4% buffered formalin. The preparation process for histological slides was as described above.

Measurement of hepatic vitellogenin (VTG) mRNA expression

Relative quantification of VTG mRNA gene expression was performed by means of a real-time RT-PCR. RNA preparation and VTG real-time RT-PCR were accomplished as previously described in Kipfer et al. (chapter A, p. 22).

RESULTS

Ontogenic gonad development

The time course of gonad development and sexual differentiation varied considerably between individuals. For instance, while at an age of 513 dph or 6000 d°C most testes of males from the Lake Thun water group displayed all sperm cell stages, there were some males with a retarded testis development showing only spermatogonia. In addition the gonad tissue of individual fish showed variation of germ cell maturation. For instance, while most oocytes within an ovary were at the Balbiani body stage, a few oocytes had progressed to the cortical alveolar stage. To standardise this intra- and inter-individual variability we used the most advanced stages of germ cell development to describe subsequently the ontogeny of sex differentiation in whitefish.

Undifferentiated gonad

Gonads of whitefish are paired cords, situated bilaterally to the swim bladder, on either side of the dorsal mesentery, extending along the full length of the peritoneal cavity and terminating at the genital pore which is associated with the urogenital papilla. Primordial gonads were observed for the first time in fish at an age of 65 dph and 491 d°C corresponding to a body length of 2 cm (Fig.2). These undifferentiated gonads contained primordial germ cells (PGCs) which measured about 8 μm in diameter and were characterised by a large, round and basophilic nucleus surrounded by few clear cytoplasm. Often there was a small space between the PGCs and their surrounding somatic cells. The transition to ovaries or testes was indicated by the development of oogonia and spermatogonia, respectively. Histologically, oogonia and spermatogonia at this early stage were almost identical and also difficult to distinguish from PGCs. Compared to PGCs, the putative oogonia and spermatogonia were slightly larger (~10 μm in diameter), had a reduced nucleus-cytoplasm ratio and the nucleus showed heterochromatous structures.

Ovarian differentiation

Ovarian differentiation preceded testicular differentiation, starting in the Lake Thun water group at 147 dph or 1820 d°C and in the spring water group at 202 dph or 1734 d°C, respectively, when fish measured 3.5 cm (spring water group: 5.5 cm) in length (Fig.2). The early ovary was identifiable by the presence of pre-meiotic oocytes in the leptotene stage (often referred to as the “bouquet stage”, characterized by finger-like structures in the nucleus, and ~7 μm in diameter) and the zygotene stage (named as “chromatin-nucleolus stage”, recognized by a single large basophilic nucleolus in the nucleus, and a slightly bigger

size (approx. 30 μm in diameter)). These germ cell stages were observed during a short time period in the Lake Thun water group (53 days from 147 dph to 200 dph, or approx. 1000 d°C), but more prolonged in the spring water group with lower temperatures (233 days from 202 dph to 435 dph, or approx. 2000 d°C). They occurred at a time were fish experienced a significant boost in body growth: from 3.5 cm to 10 cm in the Lake Thun water group, and from 5.5 cm to 8.5 cm in the spring water group. Simultaneously to the presence of germ cells at the bouquet and chromatin-nucleolus stage, the ovaries started to form typical lamellar structures. Together with the pre-meiotic germ cell stages, the lamellar structures made the transition from the undifferentiated gonad into ovarian tissue clearly evident. The next stage in oocyte development was the perinucleolar stage (diplotene phase) which was observed from 169 dph or 2298 d°C onwards, when fish had a length of 7 cm (spring water group: 232 dph, 1989 d°C, 6.5 cm). Perinucleolar stage germ cells are characterized by the presence of nucleoli at the periphery of the nucleus, and an increased size compared to the earlier stages (up to 60 μm in diameter). Shortly after the perinucleolar stage, at 200 dph and 2878 degree-days, a further stage of primary oocytes occurred, represented by the Balbiani body stage (spring water group: 295 dph, 2525 d°C, 7.5 cm). This cell stage is characterized by a further increased cell size (up to 80 μm). At 200 dph and 2878 d°C, the first oocytes of the cortical alveolus stage appeared, measuring 90 μm in diameter (spring water group: 335 dph, 2865 d°C, 7.5 cm). From that time onward, the development of oocytes remained quiescent for almost one year (313 days) in the Lake Thun water group, and almost two years (640 days) in the spring water group. The only change in this period was an increase of the cortical alveolus oocytes in size up to 330 μm. The first vitellogenic oocytes were noticed at 513 dph and 5969 d°C, when fish measured at least 17.5 cm (spring water group: 975 dph, 8305 d°C, 16.5 cm). In the Lake Thun water group, the first ripe and ovulated ova, in ovaries otherwise dominated by oocytes of the cortico alveolar stage, appeared shortly before the completion of the second year at 678 dph and 8163 d°C when fish measured 18 cm. In the spring water group, this stage occurred almost one year later at 981 dph or 8356 d°C, respectively, when fish measured 19 cm.

A formation of an ovarian cavity was not recognised in any fish.

Testicular differentiation

The onset of testicular differentiation was identified in the Lake Thun water group at 259 dph, 3673 d°C, and a fish length of 11.5 cm, when somatic cells started to form testis lobules (spring water group: 232 dph, 1989 d°C, 6.5 cm). Before that time, the presumptive testes could not be clearly recognised due to the lack of specific features signalling the onset of testicular differentiation as seen in other fish species (see Strüssmann & Nakamura, 2002):

(i) spermatogonia were hardly to differentiate from PGCs, (ii) spermatogonia and oogonia of the ovaries were histologically not discernable, (iii) somatic cells of the presumptive testis did not seem to be arranged differently than in the presumptive ovary, as it is described in other fish species (van Aerle et al., 2004; Patino & Redding, 2000), (iv) no development of an ovarian cavity in females, which could be used as an early sign to distinguish between testes and ovaries. However, around 200 dph or 2878 d°C and at a fish length of 10 cm in the Lake Thun water group, about 53 days after ovarian differentiation had started, it could be assumed that the remaining fish still showing undifferentiated gonads represented male fish.

Spermatogonia were first unequivocally identifiable when they entered meiosis, which was at 513 days and 5969 d°C in the Lake Thun water group, when fish measured more than 15 cm in body length (spring water group: 265 dph, 2270 d°C, 7.5 cm). From that time on, all germ cell stages up to spermatozoa developed within a short time (Fig.2). Compared to the ovarian differentiation, testicular differentiation was delayed (Lake Thun water group: 112 days or 1058 d°C; spring water group:30 days or 255 d°C), but, once started, proved to be fast, continuous and did not show “resting phases” as observed for ovarian differentiation between the cortical alveolar stage and the appearance of vitellogenic oocytes. The first male with ripe milt was recognised at the same time as the first females with ripe ovulated ova, at 678 dph and 8163 d°C, measuring 19 cm in the Lake Thun water group (spring water group: 981 dph, 8356 d°C, 15 cm).

Morphological gonadal deviations from normal development

Constricted and asymmetric gonads (Fig.3) were found already early in the ontogenetic gonadal development in fish of our experiment. Constrictions occurred for the first time at 291 dph and 3949 d°C and at a body length of 13 cm in the Lake Thun water group (spring water group: 650 dph; 5542 d°C; 18 cm). Asymmetry was first seen at 508 dph and 5900 d°C and a length of 15 cm in the Lake Thun water group (spring water group: 981 dph; 8356 d°C; 17.3 cm). Constrictions were present in 4% of fish from the Lake Thun water group and 11% of fish from the spring water group. Asymmetrical gonads appeared in 0.6% of the fish from the Lake water group, and 0.9% of those from the spring water group.

Atrophy/aplasia and compartmentations, two further morphological gonad deviation types typical for Lake Thun whitefish, were rarely perceived (0.9%) in our rearing experiment, and occurred only in the spring water group at a advanced stage of gonad development (> 975 days, > 8305 d°C; > 15.5 cm). Fusions of gonads with the peritoneal wall, however, an further typical gonad malformation in whitefish from Lake Thun, were never found in the two experimental groups.

Histologically, a total of 34 mosaic intersex fish were identified in our experimental groups (Tab.1). Intersex fish occurred with comparable frequencies in the Lake Thun (8.0%) and the spring water group (9.4%) (Fisher's Exact Test; P=0.72). Conversely, intersex gonads in whitefish from both treatments were significantly more frequent than mosaic intersex gonads in adult wild fish from Lake Thun, where 3 specimens out of 275 fish showed testicular oocytes(1.1%) (Fisher's Exact Test; P<0.0003).

Thirty-one out of 34 intersex fish were exclusively of the "mosaic gonad type" (Kinnison et al., 2000) also termed as "multifocal distribution type" (Nolan et al., 2001). In mosaic intersex fish, ooyctes are scattered in testicular tissue or spermatogenic cells develop in ovarian tissue (Fig.4). Only three specimen displayed beside the mosaic type also the "lobular gonad type" (Kinnison et al., 2000) or "focal distribution type" (Nolan et al., 2001), characterised by confined sections of ovarian and testicular tissue along a gonad strand, often separated by undifferentiated connective tissue (Fig.4d).

Intersex fish were observed for the first time shortly after the onset of the ovarian differentiation (in the Lake Thun water group at 169 dph, 2298 d°C, 7 cm body length; in the spring water group at 202 dph, 1734 d°C, 4 cm body length) (Fig.5). These fish showed the typical lamellar structure of a distinct ovary (ovarian lamellae) with primary oocytes and the occurrence of single or rarely multiple spermatogenic cell nests (Fig.4a). These nests usually consisted of spermatocytes and less frequently of spermatids. This mosaic gonad type with predominantly ovarian character became less frequent during the further gonadal development of whitefish (Fig.5). By contrast, the mosaic intersex type of predominantly testicular tissue with scattered primary oocytes became more prevalent (Fig.4b). This type occurred for the first time shortly after the onset of testicular differentiation and could be recognized until the end of the experiment when fish were mature (Fig.5).

Vitellogenin

VTG mRNA concentrations in males did not differ significantly between the two treatment groups (Kruskal Wallis Z Test; z=1.04; N_{Thoune}=8; $N_{Spring\ water}$ = 7; P>0.05). VTG concentration in males ranged between 0.0005 to 3.24 copies VTG mRNA/1000 copies 18s-RNA (Fig.6). VTG values in females were three (Lake Thun group) to five orders (Spring water group) of magnitude greater than male values. Females in the spring water group showed greater VTG values than those of the Lake Thun water group reflecting the different developmental stages: Females of the Lake Thun water group measured for VTG were in the early VTG stage, whereas females of the spring water group were in the late VTG stage shortly before maturity.

DISCUSSION

This paper presents the first histological characterization of the entire gonadal differentiation in an European whitefish species from hatching until maturity under controlled conditions. Furthermore, it provides a detailed description of the ontogenetic manifestation of morphological traits deviating from the normal gonadal arrangement.

Though there is detailed knowledge of gonad development in species used in aquaculture (reviewed by Nakamura et al. 1998; Baroiller & D'Cotta, 2001; Piferrer, 2001; Strüssmann et al. 2002) and species used for toxicological studies (zebrafish *Danio rerio*, Maack & Segner, 2003; medaka *Orycias latipes*, Hamaguchi, 1992; fathead minnow *Pimephales promelas*, van Aerle et al., 2004), information about differentiation in field species is less frequent, and very rare for whitefish (*Coregonus* sp.) in particular (Dlugosz & Demska-Zakes, 1992; Bogdanova, 2002; Krol et al., 2003). The results show that whitefish develop as gonochorist, with males differentiating later than females. Undifferentiated gonad anlagen were first seen at 65 dph. This is late compared with warm water species (*Danio rerio*: 10dph (van Aerle et al., 2004); *Oreochromis mossambicus*: 20 dph (Nakamura & Takahashi, 1973)), but also when compared to certain cold water species (*Oncorhynchus mykiss*: 16-29 dph (van den Hurk & Slof, 1981). However, the appearance of undifferentiated gonad anlagen in whitefish from our study is only slightly later than in other coregonid species (*C. peled*: 39 dph; (Krol et al, 2003); *C. lavaretus*: 47 dph (Dlugosz et al., 1992); *C.peled* x *C.nasus*: 40 dph (Bogdanova, 2002)). Besides species differences, water temperature is an important modulating factor. In the Lake Thun water group, water temperature was 5.5 – 6.5°C in the first two months after hatch and was thus significantly colder than in the experiment of Dlugosz et al., 1992 (> 7°C) and Kroll et al., 2003 (10°C). This explains the slight delay of the appearance of the gonad anlagen from our Lake Thun fish compared to other coregonid studies. In the Spring water group with constant water temperatures of 8-9°C, gonad development was clearly delayed in respect to the age but advanced in respect to fish size, compared to the Lake Thun water group: Gonad development retardation in the spring water group was paralleled by a reduced growth. Fish of this group reached the gonad development stages with smaller sizes compared to the Lake Thun water group. This was more prominent in males than in females. Differences in temporal development between these two groups blur, however, if the ontogenetic development is described by degree-days (sum of the mean daily water temperatures). The development from the gonad anlage to the mature gonad requires 8100 to 8300 d°C, which corresponds almost to a 2-year-period (in the Lake Thun water group 678 days).

Whitefish populations of Lake Thun have previously been reported to show high prevalence of gonad deformations (Bernet et al. 2004, Bittner et al., submitted). The present study demonstrates that in whitefish reared under artificial conditions, the morphological gonad deviations described in wild whitefish from Lake Thun - with the exception of fusions - can become manifest concomitant with gonad differentiation. Intersex fish developed from the very beginning of sexual differentiation (i.e. 169 dph, 2298 d°C, 7 cm fish in the Lake Thun water group). Constrictions and asymmetries, developed for the first time in the first (0+) or second (1+) year-of-life, at a body length of 13-18 cm. Aplasia and compartmentation were recorded in the third (2+) year-of-life at a body length of 16-18 cm.

Comparing the gonad deviations in the population of wild fish from Lake Thun and those of the experimentally reared fish, two findings are striking: Firstly, the frequencies of the macroscopic morphological deviations constrictions, asymmetries, aplasia and compartmentation were significantly lower in experimentally reared fish than in wild whitefish from Lake Thun. Whitefish caught in Lake Thun displayed gonad constrictions in 64% of mature males and 3% of mature females during the spawning season, while fish sampled throughout the year had constrictions in 1% (females) to 13% (males) (Bittner et al., 2007). Asymmetrical gonads, where the volume of one strand was $\leq$ 50% of the other, were found in 14% of females during the spawning period and in 8% of females and 4% of males throughout the year (Bittner et al., 2007). Secondly, in contrast, the formation of microscopic intersex gonads during the gonadal developing and differentiation process in the experimentally reared whitefish was significantly more frequent than intersex in Lake Thun whitefish.

For the low frequency the macroscopical morphology deviations, there are two possible reasons. Firstly, the reared fish from our experiment are biased by the age factor as the highest frequencies of gonad alterations in whitefish populations from Lake Thun were reported in 3- to 5- year-old-fish (Bernet et al., 2004). The oldest fish in the present experiment were of an age of 2.5 years. This probably results in an insufficient time to fully develop deviated gonads. And secondly, an unknown crucial causative exogenous factor in the Lake Thun ecosystem (i.e. a water contaminant) may be responsible for the development of the gonad malformation, and this factor may have been missing in our experimental setup.

In contrast, data of our study report a surprisingly high frequency of 8-9% mosaic intersex fish during the gonadal sex differentiation in a gonochoristic species. Mosaic intersex in wild whitefish from Lake Thun occurred in 1.1% of the fish (this study) and another approximately 1% of wild fish from Lake Thun displays lobular intersex (Bernet et al., 2004; Bittner et al., submitted). Although intersex fish are regularly reported in gonochorist species (i.e. Nolan,

2001; Sumpter & Johnson, 2005) and even whitefish species (see review of Kinnison et al, 2000 and Bernet et al., 2004) they are considered as an uncommon phenomenon. The high frequency of mosaic intersex fish during gonad development raises the question about the correct evaluation of intersex stages in respect to normality and abnormality, respectively. There is some evidence that intersex in gonochorist fish is linked with the presence of man-made estrogenic substances in the aquatic environment (i.e. Purdom et al., 1994; Jobling et al, 1998). However, the problem is, that there is generally little information about the correct interpretation of artificially induced intersex fish (i.e. due to estrogenic substances) and the normal occurrence of intersex fish in the population or during ontogenetic sex differentiation due to lacking baseline data (Sumpter & Johnson, 2005). We suppose that our results give evidence for a naturally increased mosaic intersex condition in whitefish during the ontogenetic gonadal differentiation process, without involvement of exogenic endocrine active substances. Our hypothesis is based on the following results:

- There is an increased intersex frequency of 8-9.4% of the individuals from all the experimental treatment groups, independently from water quality, water temperature, and feed. Even in the spring water group, where the presence of endocrine active compounds is very improbable due to the remote nature of the source, the intersex frequency of these fish is comparable to that of fish from the Lake Thun water group.
- There is no evidence of any endocrine disrupting component according to the VTG concentration measured in males. Male whitefish showed 3 to 5 orders of magnitude lower VTG concentration than females. There is no difference in VTG concentrations between males from the Lake Thun and the spring water group.
- With the exception of three specimen, all intersex fish were of the mosaic type. Shortly after the onset of ovarian differentiation, mosaic intersex occurred predominantly in ovarian gonads characterized by scattered single or rarely multiple spermatogenic cell nests. Whereas in the further development mosaic intersex in predominantly ovarian tissue became less and less frequent, intersex of the mosaic type in gonads dominated by testicular tissue interspersed by scattered oocytes significantly increased. Mosaic intersex in predominantly testicular tissue is also found in wild fish from the Lake Thun population, however, significantly less frequent than in fish from our experimental treatment groups. Fish from the Lake Thun population were significantly older (average age:3 years; min.: 1 year; max: 7 years) than the fish from our experiment (average age: 1 year; min.: 0 year; max: 2 years). The wild fish participated at least in one spawning period and have, therefore, definitely finalised their process of gonadal differentiation.

- We suppose that an increased natural frequency of mosaic intersex fish has been undetected so far, due to lacking studies describing the gonad differentiation process in whitefish. Germ cell differentiation in European whitefish (*Coregonus lavaretus*) is described by Dlugosz & Demska-Zakes (1992), but only up to the onset of the perinucleolar stage germ cells at 166 days post hatch. No intersex fish occurred in our experiments during this early ontogenetic differentiation period. Krol et al. (2003) described the sexual differentiation process in the Siberian species *Coregonus peled* up to an age of 102 dph. Fish of this study have not reached an age where the first intersex specimes would appear as well. In a third study, where the influence of hybridisation of *C. peled* with *C. nasus* on the ontogenetic gonad development was studied, the occurrence of some females with male sex cells are mentioned (Bogdanova, 2002). Unfortunately the prevalence of specimens of this type are not further addressed.
- The natural occurrence of mosaic intersex fish at low frequencies independent from any influence of endocrine disrupting substances are described in other gonochoristic species, like brown trout *Salmo trutta* (Ashby et al., 1965; Körner et al., 2005) and rainbow trout *Oncorhynchus mykiss* (Schwaiger et al., 2002; Jobling et al., 1998)

The presence of testicular oocytes as a natural phenomenon during ontogeny and decrease of the frequency as the fish matured are in coincidence with studies on gonadal development in African clawed frogs (*Xenopus laevis*) exposed to atrazine under outdoor microcosm conditions (Jooste et al., 2005). The authors report a 39% -59% prevalence of intersex recently metamorphosed frogs, independently of the atrazine concentration. Ten month after the metamorphosis, another subset of juveniles was examined, and both the frequency of intersex frogs (0% - 40%) and the number of testicular oocytes per individual was less.

We suppose that mosaic intersex specimens in whitefish are a consequence of focal failure in the development of the bivalent undifferentiated primordial germ cells during the differentiation process. Among gonochorists, as whitefish, having male and female sexes in separate individuals, the ultimate fate of the developing gonads is governed by a delicate balance of genetic and environmental factors (Strüssmann & Nakamura, 2002), not seldom resulting in a phenotypical sex different from that determined genotypically. The differentiation of PGC is essentially triggered by sex steroids and enzymes like aromatase inhibitors (Pifferer, 2001). Slight focal variations in the concentration of steroid and enzyme patterns can result in an aberrant focal phenotypical sex differentiation of single or few PGCs, resulting in intersex condition during onogeny.

ACKNOWLEDGEMENTS

We would like to express our gratitude to the Fisheries Inspectorate of Bern for financial support, infrastructure facilities, sampling of whitefish from Lake Thun and especially for their help in fish maintenance and plankton fishing, in particular to M. Flück, U. Gutmann, H. Haussener, Ch. Küng, U. Lehmann and H. Walter. HU. Kernen is owed for his help in keeping fish of the Lake Thun water group. The fishermen K. Klopfenstein, H. Moser and H. Sieber helped us obtaining parental whitefish from Lake Thun for our rearing experiments. A. Brügger supported us with cutting and reading histological slides. This work was funded in parts by a grant from the Swiss National Science Foundation (Grant 405040-106986/1).

REFERENCES

Ashby, K.R. (1965). The effect of steroid hormones on the development of the reproductive system of *Salmo trutta* L. when administered at the commencement of spermatogenic activity in the testes. Revista de Biologia 58: 139-169.

Atkinson, D., 1994. Temperature and organism size – a biological law for ectotherms? Advanced ecological research 25: 1-58.

Baroiller, J.-F. & D'Cotta, H. (2001). Environment and sex determination in farmed fish. Comparative Biochemistry and Physiology 130C: 399-409.

Bittner, D., Bernet, D., Wahli, T., Segner, H., Küng, C., Largiader, C.R. (submitted) How normal is abnormal? – Discriminating between deformations and natural variation in gonad morphology of European whitefish *Coregonus lavaretus* (L.) from Swiss lakes.

Bogdanova, V.A. (2002). Ontogenesis of gonads in *Coregonus peled* (Gmelin) x *Coregonus nasus* (Pallas) hybrids. Arch. Hydrobiol. Spec. Issues Advanc. Limnol. 57: 243-252.

Demska-Zakes, K., Mamcarz, A., 1996. Gonadal abnormalities in *Coregonus peled* Gmel. x *Coregonus lavaretus* L. hybrids, introduced into natural waters. In*:* Kirchhofer, A., Hefti, D. (Eds.), Conservation of endangered freshwater fish in Europe. Birkhäuser, Basel, pp. 225-232.

Devlin, R.H. & Nagahama, Y. (2002) Sex determination and sex differentiation in fish: an overview of genetical, physiological, and environmental influences. Aquaculture 208: 191-364.

Dlugosz, M. & Demska-Zakes, K. (1992). Sex differentiation in European Whitefish (*Coregonus lavaretus* L.). Po. Arch. Hydrobiol. 39:633-640.

Fitzsimons, J.D., Cairns, V.W., 2000. Prevalence of a testicular anomaly in lake trout (*Salvelinus namaycush*) of the Great Lakes basin. Journal of Great Lakes Research 26, 74-81.

Hamaguchi, S. (1992) Sex differentiation of germ cells and their supporting cells in *Oryzias latipes*. The Fish Biology Journal Medaka 4: 11-18.

Jobling, S. , Nolan, M., Tyler, C.B., Brighty, G., Sumpter, J.P. 1998. Widespread sexual disruption in wild fish. Environmental Science & Technology 32: 2498-2506.

Jooste AM, Du Preez LH, Carr JA, Giesy JP, Gross TS, Kendall RJ, Smith EE, Van der Kraak GL, Solomon KR (2005). Gonadal development of larval male *Xenopus laevis*

exposed to atrazine in outdoor microcosms. Environmental science & technology 39 (14): 5255-5261.

Kinnison MT, Unwin MJ, Jara F (2000) Macroscopic intersexuality in salmonid fish. N Z J Mar Fresh Res 34:125-134

Körner, O., Vermeissen, E.L.M., Burkhardt-Holm, P. (2005). Intersex in feral brown trout from Swiss midland rivers. Journal of Fish Biology 67: 1734-1740.

Krol, J., Demska-Zakes, K., Hliwa, P., Korzeniowska, G. (2003). The Influence of temperature on the sex differentiation process in peled *Coregonus peled* (Gmel.). Archives of Polish Fisheries 11/1:23-31.

Maack, G. & Segner, H. (2003) Morphological development of the gonads in zebrafish. Journal of Biology 62: 895-906.

Mikaelian I, Martineau D, De Lafontaine Y, Harshbarger JC, Lee LLJ (2002) Health of lake whitefish (*Coregonus clupeaformis*) with elevated tissue levels of environmental contaminations. Environ Toxicol Chem 21:532-541

Nakamura M., Kobayashi, T., Chang, X.-T., Nagahama, Y. (1998) Gonadal sex differentiation in teleost fish. The Journal of Experimental Zoology 281: 361-372.

Neuheimer, A. B.; Taggart, C. T. (2007) The growing degree-day and fish size-at-age: the overlooked metric. Canadian Journal of Fisheries and Aquatic Sciences 64: 375-385.

Nolan, M., Jobling, S., Brighty, G., Sumpter, J.P., Tyler, C.R. (2001). A histological description of intersexuality in the roach. Journal of Fish Biology 58: 160-176.

Patino, R. & Redding, J. (2000). Microscopical functional anatomy: Reproductive systems. In: Handbook of Experimental Animals, The Laboratory Fish (Ostrander, G.K., ed.), pp. 489-500. London, Academic Press.

Pifferer, F. (2001). Endocrine sex control strategies for the feminization of teleost fish. Aquaculture 197: 229-281.

Purdom; C.E., Hardiman, P.A., Bye, V.J., Eno, N.C., Tyler, C.R., Sumpter, J.P. 1994: Estrogenic effects of effluents from sewage treatment works. Chem. Ecol. 8: 275-285.

Rodgers-Gray, T.P., Jobling, S., Kelly, C., Morris, S., Brighty, G., Waldock, M.J., Sumpter, J.P., Tyler, C.R., 2001. Exposure of juvenile roach (*Rutilus rutilus*) to treated sewage effluent induces dose-dependent and persistent disruption in gonadal duct development. Environmental Science & Technology 35, 462-470.

Ruby, S.M., Cairns, V., 1983. Implications of testicular constrictions on spermatogenesis in lake Ontario lake trout, *Salvelinus namaycush*. Journal of Fish Biology 23, 385-395.

Schwaiger, J., Mallow, U., Ferling, H., Knoerr, S., Braunbeck, T., Kalbfus, W., Negele, R.D. (2002). How estrogenic is nonylphenol? A transgenerational study using rainbow trout (*Oncorhynchus mykiss*) as a test organism. Aquatic Toxicology 59: 177-189.

Strüssmann, C.A. & Nakamura, M. (2002). Morphology, endocrinology, and environmental modulation of gonadal sex differentiation in teleost fish. Fish Physiology and Biochemistry 26: 13-29.

Strüssmann, C.A., Karube, M., Miranda, L.A., Patino, R., Somoza, G.M., Uchida, D., Yamashita, M. (2002). Methods of sex control in fishes and an overview of novel hypotheses concerning the mechanisms of sex differentiation. In: Fish genetics and aquaculture biotechnology. Ed. by T.J. Pandian, C.A. Strüssmann & Marian, M.P., Oxford & IBH Publishing/Science Publishers, New Delhi, India/Enfield, USA.

Sumpter, J.P., Johnson, A.C. (2005) Lessons from the endocrine disruption and their application to other issues concerning trace organics in the aquatic environment. Environmental Science & Technology 39: 4321-4332.

van Aerle R., T.J. Runnalls, C.R. Tyler (2004): Ontogeny of gonadal sex development relative to growth in fathead minnow. Journal of Fish Biology 64: 355-369.

Wicklund, T., Lounasheimo, L., Lom, J., Bylund, G., 1996. Gonadal impairment in roach *Rutilus rutilus* from Finnish coastal areas of the northern Baltic sea. Diseases of Aquatic Organisms 26, 163-171.

TABLES

Tab.1: Frequency of mosaic intersex fish both from the different treatments over the whole sampling periods, and the feral fish from Lake Thun. Given is the number of fish analysed (N fish), the number of intersex fish (N) and their relative frequency (%), as well as 95% confidence intervals based on binomial distribution (CI_{95}).

		Intersex		
	N fish	N	%	CI_{95}
Treatment groups				
Lake Thun water group	175	14	8.0	4.4 – 13.1
Spring water group	213	20	9.4	5.8 – 14.1
Adult, feral fish from Lake Thun	275	3	1.1	0.2 - 3.2

FIGURES

Figure captions

Fig.1: Water temperature regime of Lake Thun during the experimental period 2003 to 2005 and of the spring water during the experimental period 2005 to 2007.

Fig.2: Occurrence of various germ cell types and achievement of functional maturity in ovaries (F) and testes (M) of fish from the Lake Thun water group (black bars) and the spring water group (grey bars), in relation to (a) degree-days post hatch, (b) age (days post hatch) and (c) body length. Data are shown for the most advanced fish within the sample. The numbers near the bars represent the first (left to the bar) and/or last (right to the bar) occurrence of the particular cell type stage as exact values. The grey bars for the primordial germ cells of the spring water treatment group are dashed, because the first sampling of this group took place after the development of undifferentiated gonads, but shortly before onset of female differentiation. Fish were assessed as functional „mature“, as soon as ripe germ cells, i.e. ovulated oocytes or milt, were released.

Fig.3: Two morphological gonad deviations from normal development of gonads. (a) Constrictions (arrowhead) in the right testis of a fish from the Lake Thun water group, at 291 dph, 3949 d°C and 12.5 cm body length. (b) Asymmetrical ovaries of a female from the Lake Thun water group, at 503 dph, 5900 d°C and 15 cm body length.

Fig.4: Transverse sections through mosaic intersex gonads. (a) Mosaic intersex in a putative ovarian tissue showing the typical lamellar structure at an early developmental stage with oocytes at the chromatin-nucleolar stage (cn), oogonia arranged around the ovarian lamellae and the presence of two nests containing spermatocytes (sc) and spermatids (st). Fish from the spring water group, age: 295 dph, 2525 d°C, 7.5 cm. (b) Mosaic intersex in a putative testicular tissue showing the lobular testis structure at an early developmental stage with presumptive spermatogonia (sg) and a few oocytes at the chromatin-nucleolar stage (cn) arranged around the lobules. Fish from the spring water group, age: 232 dph, 1989 d°C, 6 cm. (c) Severe mosaic intersex in an ovarian tissue, showing the typical lamellar structure,

presence of primary oocytes mostly at the cortical alveolus stage (cao) and nests containing spermatogenic cells (sp). Fish from the Lake Thun water group, age: 200 dph, 2878 d°C, 8 cm. (d) Lobular and mosaic intersex, showing on the left side ovarian tissue (o) with the typical lamellar structure and oocytes at the Balbiani body stage (Bbo) and at the early cortical alveolus stage (cao), well separated from the predominately testicular tissue (t) on the right by a constriction (con). The testicular tissue characterised by a lobular structure and the presence of presumptive spermatogonia is scattered by several oocytes of the Balbiani body stage. Fish from the spring water group, age: 680 dph, 5797 d°C, 12 cm.

Fig.5: Proportion of the different phenotype sexes of whitefish from the two treatments (upper: Lake Thun water group; lower: spring water group) in relation to age, expressed as degree-days post-hatch (grouped in classes of 200 degree-days). The number of fish of every sampling that were sexed histologically, is indicated above every bar.

Fig.6: VTG m-RNA concentration in liver homogenates of males, females and intersex fish from the Lake Thun and the spring water group. CON = constricted testes; COM = compartmented testes; APL = aplasia of one testicular strand. Values shown are median, 25th-75th percentiles, and minimum – maximum.

Fig.1

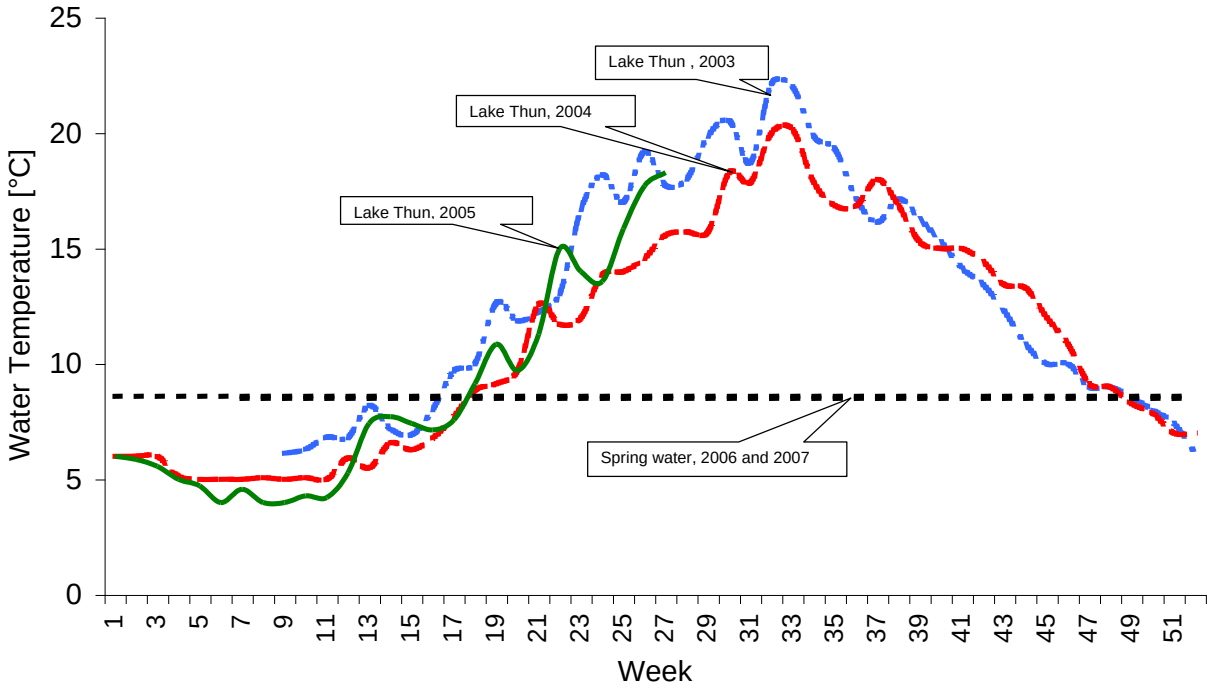
Lake Thun , 2003
Lake Thun, 2004
Lake Thun, 2005
Spring water, 2006 and 2007
Water Temperature [°C]
Week
0
5
10
15
20
25
1
3
5
7
9
11
13
15
17
19
21
23
25
27
29
31
33
35
37
39
41
43
45
47
49
51

Fig.2

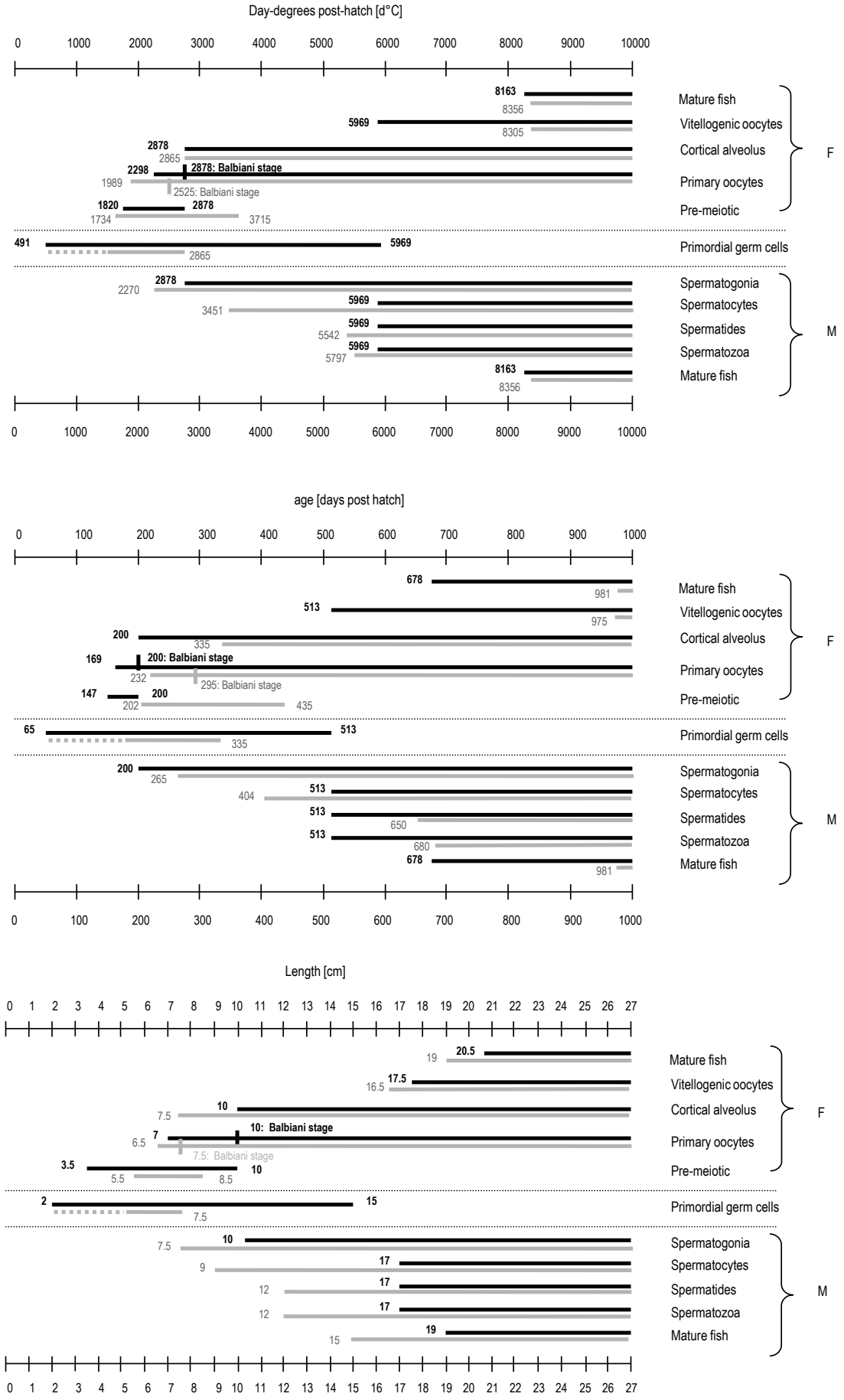
Day-degrees post-hatch [d°C]
0 1000 2000 3000 4000 5000 6000 7000 8000 9000 10000
8163
8356
5969
8305
2878
2865
2298
2878: Balbiani stage
1989
2525: Balbiani stage
1820
2878
1734
3715
491
5969
2865
2878
2270
5969
3451
5969
5542
5969
5797
8163
8356
Mature fish
Vitellogenic oocytes
Cortical alveolus
Primary oocytes
Pre-meiotic
F
Primordial germ cells
Spermatogonia
Spermatocytes
Spermatides
Spermatozoa
Mature fish
M
0 1000 2000 3000 4000 5000 6000 7000 8000 9000 10000
age [days post hatch]
0 100 200 300 400 500 600 700 800 900 1000
678
981
513
975
200
335
169
200: Balbiani stage
232
295: Balbiani stage
147
200
202
435
65
513
335
200
265
513
404
513
650
513
680
678
981
Mature fish
Vitellogenic oocytes
Cortical alveolus
Primary oocytes
Pre-meiotic
F
Primordial germ cells
Spermatogonia
Spermatocytes
Spermatides
Spermatozoa
Mature fish
M
0 100 200 300 400 500 600 700 800 900 1000
Length [cm]
0 1 2 3 4 5 6 7 8 9 10 11 12 13 14 15 16 17 18 19 20 21 22 23 24 25 26 27
19
20.5
16.5
17.5
7.5
10
6.5
7
10: Balbiani stage
7.5: Balbiani stage
3.5
10
5.5
8.5
2
15
7.5
7.5
10
9
17
12
17
12
17
15
19
Mature fish
Vitellogenic oocytes
Cortical alveolus
Primary oocytes
Pre-meiotic
F
Primordial germ cells
Spermatogonia
Spermatocytes
Spermatides
Spermatozoa
Mature fish
M
0 1 2 3 4 5 6 7 8 9 10 11 12 13 14 15 16 17 18 19 20 21 22 23 24 25 26 27

Fig.3



Fig.4:

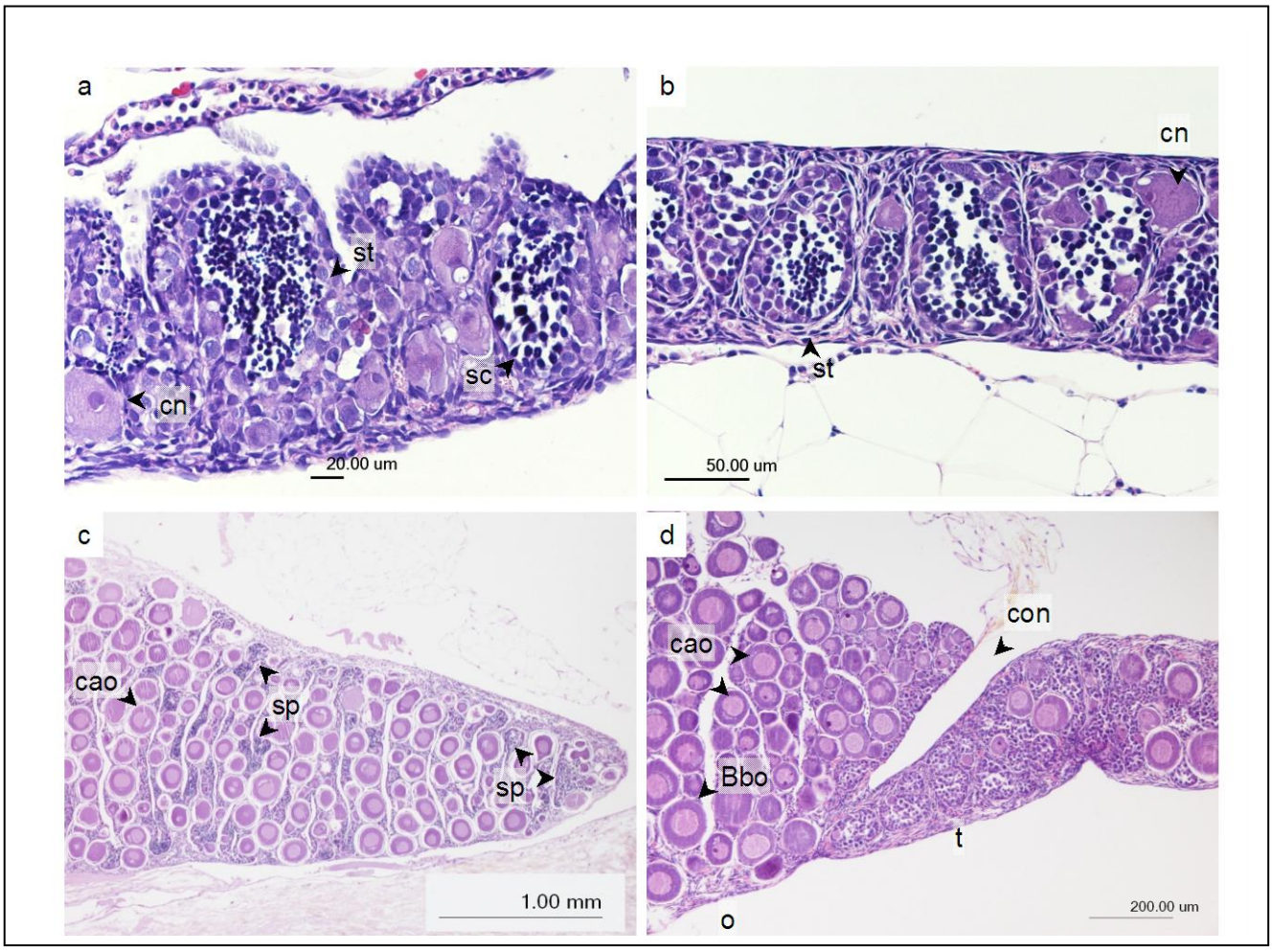
a
st
sc
cn
20.00 um
b
cn
st
50.00 um
c
cao
sp
sp
1.00 mm
d
con
cao
Bbo
t
o
200.00 um

Fig.5

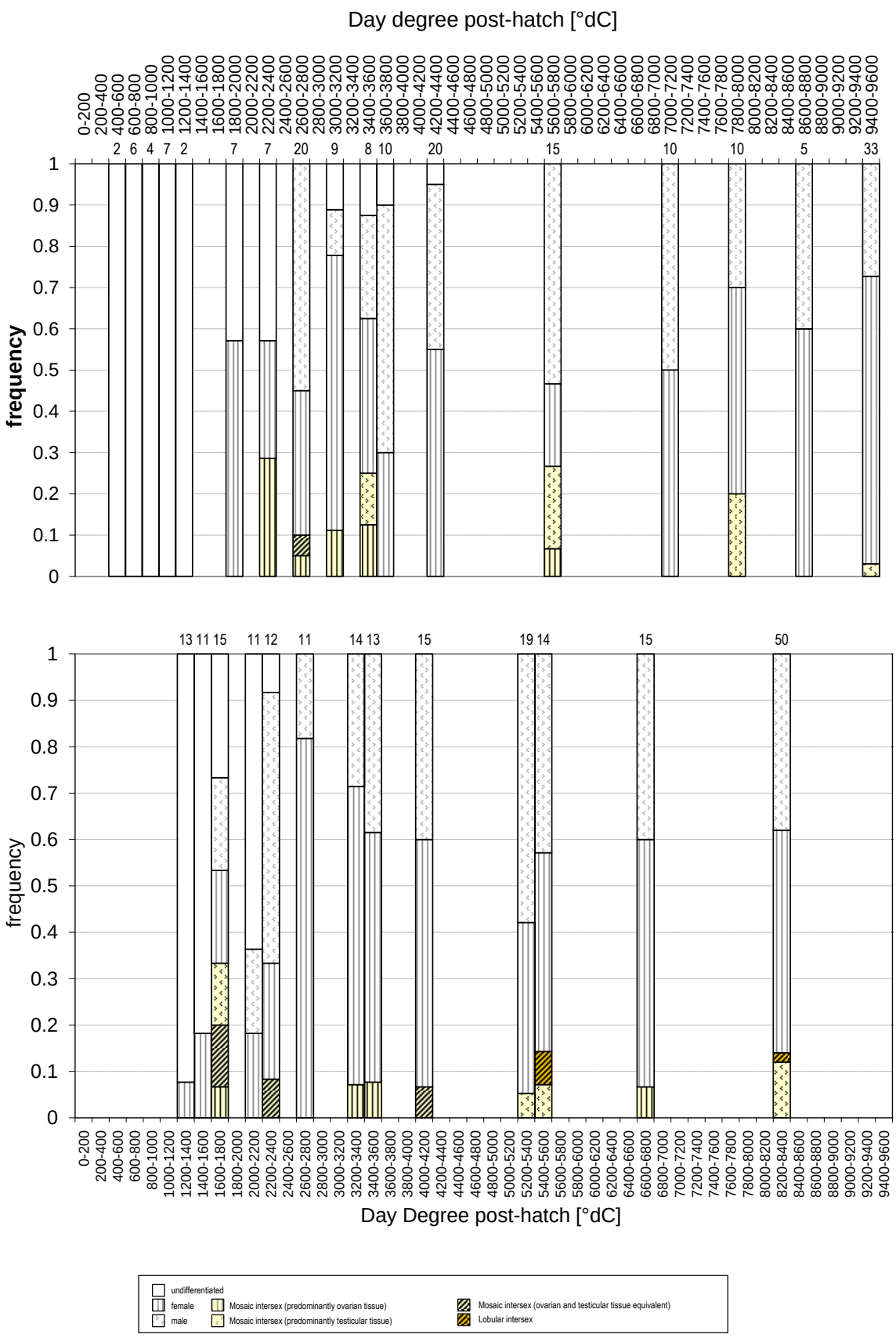
Day degree post-hatch [°dC]
frequency
Day Degree post-hatch [°dC]
undifferentiated
female
male
Mosaic intersex (predominantly ovarian tissue)
Mosaic intersex (predominantly testicular tissue)
Mosaic intersex (ovarian and testicular tissue equivalent)
Lobular intersex

Fig.6:

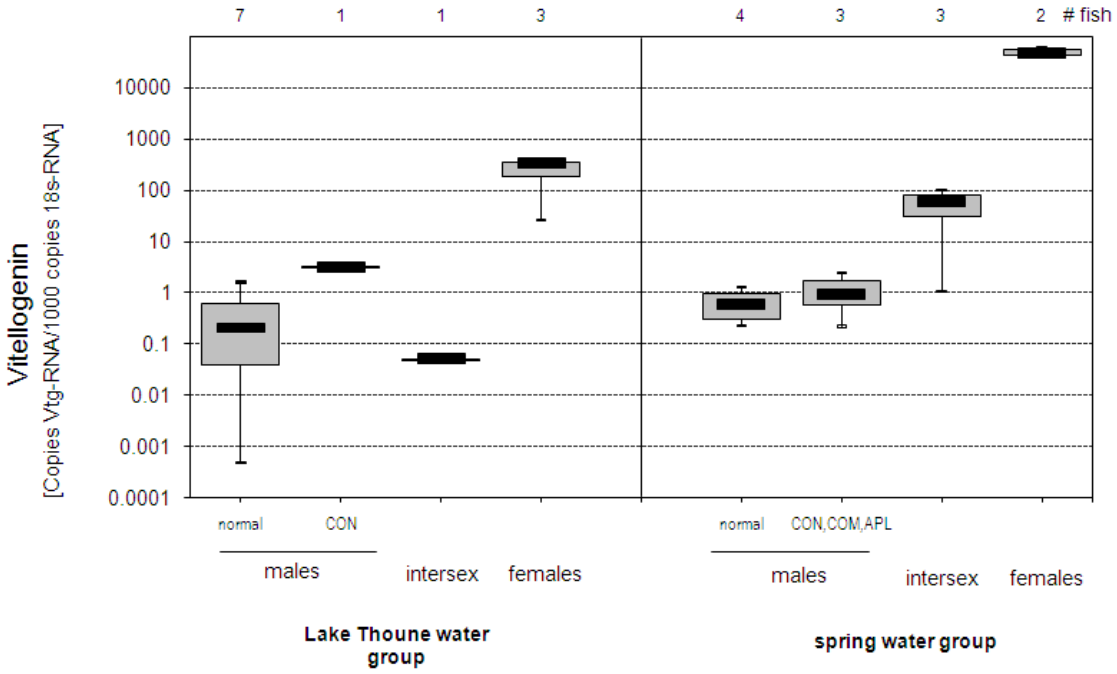
7
1
1
3
4
3
3
2
fish
Vitellogenin
[Copies Vtg-RNA/1000 copies 18s-RNA]
10000
1000
100
10
1
0.1
0.01
0.001
0.0001
normal
CON
normal
CON,COM,APL
males
intersex
females
males
intersex
females
Lake Thoune water group
spring water group

KAPITEL C

Gonadal malformations in whitefish from Lake Thun: defining the case and evaluating the role of EDCs

Daniel Bernet, Anja Liedke, David Bittner, Rik I. L. Eggen, Sibylle Kipfer, Christoph Küng, Carlo R. Largaider, Marc J.-F. Suter, Thomas Wahli, and Helmut Segner

doi:10.2533/chimia.2008.383 CHIMIA 2008, 62, No. 5

Chimia 62 (2008) 383–388
© Schweizerische Chemische Gesellschaft
ISSN 0009–4293

Gonadal Malformations in Whitefish from Lake Thun: Defining the Case and Evaluating the Role of EDCs

Daniel Bernet[a], Anja Liedtke[b], David Bittner[c], Rik I. L. Eggen[b], Sibylle Kipfer[a], Christoph Küng[d], Carlo R. Largiader[e], Marc J.-F. Suter[b], Thomas Wahli[a], and Helmut Segner[a*]

Abstract: The objectives of this project were to evaluate i) whether the gonad alterations of whitefish (*Coregonus lavaretus* spp.) in Lake Thun represent abnormal morphological variations specific to this lake, and, if so, ii) whether the malformations are related to chemical exposure, in particular to exposure to endocrine-disrupting compounds (EDCs). Large-scale monitoring data revealed that, although whitefish in other lakes display some background variation of gonad morphology, the situation in Lake Thun, is unique because of the significantly higher prevalence of gonad malformations. The abnormal variations of whitefish gonad morphology include aplasias, compartmentations, fusions, and intersex. In the search for the factor(s) causing the gonad malformations, coregonids were exposed from fertilization up to maturity to Lake Thun water and plankton or to contaminants possibly being present in the lake, including trinitrotoluenes, and naphtalene sulfonates. Since these experiments are still ongoing, a conclusive answer cannot be given yet, but initial observations point to a role of the lake plankton. The possible presence of EDCs in Lake Thun was assessed using bioanalytics and biomarkers. The bioanalytical studies found estrogenic activities in concentrated plankton extracts of Lake Thun, however, estrogenic activities occurred also in plankton extracts of reference lakes. Bioassay-directed fractionation of the plankton samples points to degradation products of natural substances as a cause of the estrogenic activity. Examination of Lake Thun whitefish for EDC biomarkers such as vitellogenin, sex steroid levels or intersex frequency yielded no indications of exposure to EDCs, neither in fish with normal nor in fish with abnormal gonad morphology. Long-term laboratory exposure of developing coregonids to the prototype estrogenic compound, 17β-estradiol, resulted in an increased frequency of intersex gonads, but did not induce the other gonad malformations typical for Lake Thun coregonids. In summing up, the currently available evidence does not support an EDC or chemical etiology of the gonad malformations, however, this preliminary conclusion needs to be substantiated in the ongoing investigations. The project also highlights the need for more detailed knowledge of natural variation in wildlife populations to be able to recognize anthropogenically caused variation.

Keywords: *Coregonus* · Endocrine disruption · Gonad malformation · Intersex

Introduction

Lake Thun is a prealpine, oligotrophic lake of 47 km^2 with a maximal depth of 217 m. Whitefish (*Coregonus lavaretus* spp.) represent the main fish species caught by commercial fishermen. Several morphologically and genetically distinct ecotypes of whitefish occupying different ecological niches occur in the lake.[1]

In 2000, commercial fishermen observed a high number of whitefish with morphologically altered gonads in their catches from Lake Thun. According to the fishermen, corresponding alterations of whitefish gonads were not observed in previous years. A subsequent detailed investigation[2] classified the gonadal morphological variations into distinguishable categories including adhesions/fusions to the peritoneal wall and the lateral trunk musculature, compartmentations, asymmetry of the left or right gonad strand, atrophy/aplasia, constrictions, and hermaphroditism (Fig. 1). Since wild fish serve as indicator for the quality of the aquatic environment and since Lake Thun serves as drinking water reservoir for nearly half a million people, it is of great public interest to evaluate to what degree the suspected gonad malformations in whitefish from Lake Thun indicate abnormal variation in gonad morphology. Moreover, if the alterations are abnormal, it will also be important to identify the underlying causes.

The high prevalence of gonadal morphological variations in Lake Thun coregonids raises the following questions:

i) To what extent do the gonad alterations of Lake Thun coregonids represent normal morphological variations in

*Correspondence: Prof. Dr. H. Segner[a]
Tel.: +41 31 631 2441 or 2465
Fax: +41 31 631 2611
E-mail: helmut.segner@itpa.unibe.ch
[a]Zentrum für Fisch- und Wildtiermedizin
Universität Bern
Postfach 8466
CH-3001 Bern
[b]Eawag
Überlandstrasse 133
CH-8600 Dübendorf
[c]Zoologisches Institut
Universität Bern
Postfach 8466
CH-3001 Bern
[d]Fischerei-Inspektorat
Schwand
CH-3110 Münsingen
[e]Institut für Klinische Chemie, Universitätspital, Universität Bern, CH-3010 Bern

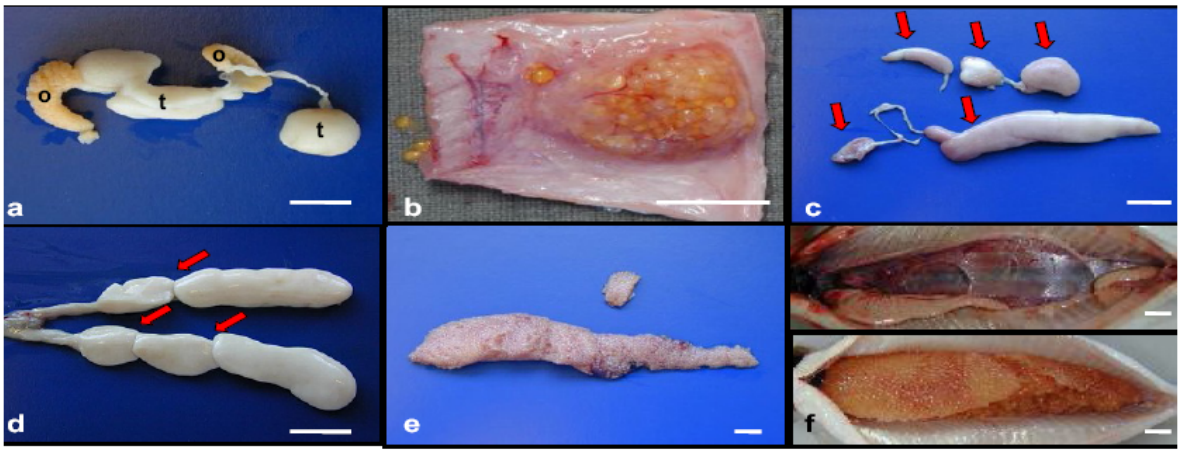

Fig. 1. Gross morphology of gonad alterations in whitefish from Lake Thun. a) Hermaphrodite gonad: Ovarian (o) and testicular lobes (t) on the same gonadal strand. b) Fusions of the gonads to the peritoneal wall and the muscles. c) Compartmented testes: The testicular strand is separated into several lobes (red arrows). d) Constrictions: Development of several lobes that are not separated from each other. e) Asymmetrical ovaries. f) Aplasia of one gonad strand. Above: The left testicular strand is missing. Below: Only the left ovarian strand is present. Bars = 1 cm.

wild whitefish populations, and is the situation in Lake Thun different to other lakes?

ii) If the alterations are abnormal, what is the factor(s) causing the alterations?

These questions were addressed through a series of experiments starting in 2004 and partly still ongoing today. In the following, a short overview of the currently available results will be given.

Are the Gonad Alterations of Lake Thun Coregonids 'Abnormal' and is the Situation in Lake Thun Unique?

Most morphological traits show some degree of quantitative and/or qualitative variation and, as stated by Sumpter and Johnson,[3] "it is axiomatic that it is not possible to conclude something is abnormal unless one knows what is normal". Thus it is crucial to clarify whether the extent of variation in gonad morphology observed in whitefish from Lake Thun goes beyond a 'natural' background level.

When initiating our studies on Lake Thun whitefish, the available information from either the literature,[4–7] or from responses to questionnaires that we had sent out to researchers all over the world, did not provide any clue with regard to 'normal' levels of variation in coregonid gonad morphology. To overcome this situation we

i) performed a regular monthly monitoring of the whitefish catch of commercial fishermen in Lake Thun,

ii) extended the monitoring to two neighboring lakes, Lake Brienz and Lake Biel, in which morphologically altered gonads of whitefish had not been reported so far, and

iii) included a second monitoring strategy by sampling mature fish on the spawning sites in all three lakes.

We analyzed the variation in gonad morphology at three hierarchical levels

i) among the lakes,

ii) among whitefish ecoforms within lakes, and

iii) among spawning sites within the coregonid ecoforms.

With both monitoring strategies it was found that gonad morphological variations were not restricted to coregonids of Lake Thun but were also present in whitefish populations of the two neighboring lakes. Asymmetries, which were most prevalent in females, and constrictions, which were most prevalent in males, occurred at comparable frequencies in the whitefish populations of all three lakes.[8] The situation in Lake Thun, however, was different because of significantly higher prevalence of aplasia, compartmentations, fusions, and intersex. Among the four ecoforms of coregonids being present in Lake Thun, the so-called 'Brienzlig' showed the highest frequency of gonad alterations,[2,8] and males were generally more affected than females (Fig. 2). These findings enabled discrimination between normal and abnormal variation in gonad morphology: Aplasia, compartmentations, fusions, and intersex are apparently 'abnormal' variations or malformations, whereas asymmetries and constrictions appear to represent natural variations of coregonid gonad morphology.[8]

What is the Factor Causing the Alterations?

Gross alterations of gonad morphology have been reported for a variety of fish species from a number of field studies.[9–13] In many of the published cases, the etiology of the gonadal alteration is not known. As a matter of fact, gonad morphology of fish is susceptible to many environmental factors. For instance, infestation by the parasite *Pleistophora mirandellae* can lead to gonad histological alterations.[14] In Lake Thun coregonids, gonad parasites were never observed among the approximately 400 individuals examined histologically. Interestingly, however, *Pleistophora mirandellae*-induced gonad alterations were observed in brown trout (*Salmo trutta fario*) populations from tributaries to Lake Thun (Bernet, unpublished).

Another environmental factor that frequently has been associated with morphological alterations of fish gonads are contaminants[e.g.11,15,16]. Particularly the so-called endocrine-disrupting compounds (EDCs), *i.e.* substances that mimic endogenous hormones or modulate their metabolism, are able to modify the morphology of developing gonads or of already differentiated gonads. This has been shown in numerous laboratory experiments[e.g.17,18] as well as in field studies.[e.g.19,20] Probably the best documented example of an association between EDC exposure and gonad morphological alterations are the findings on roach, *Rutilus rutilus*, showing high frequencies of intersexuality (*i.e.* the presence of both male and female gonadal characteristics within the same gonad) in many populations of UK rivers.[21] The strong correlation of intersex frequency with the proximity of the roach populations to sewage treatment plants (STPs) point to a causal relationship between estrogenic chemicals in the effluents and the presence of the intersex gonads.[22] Also

CHIMIA 2008, 62, No. 5

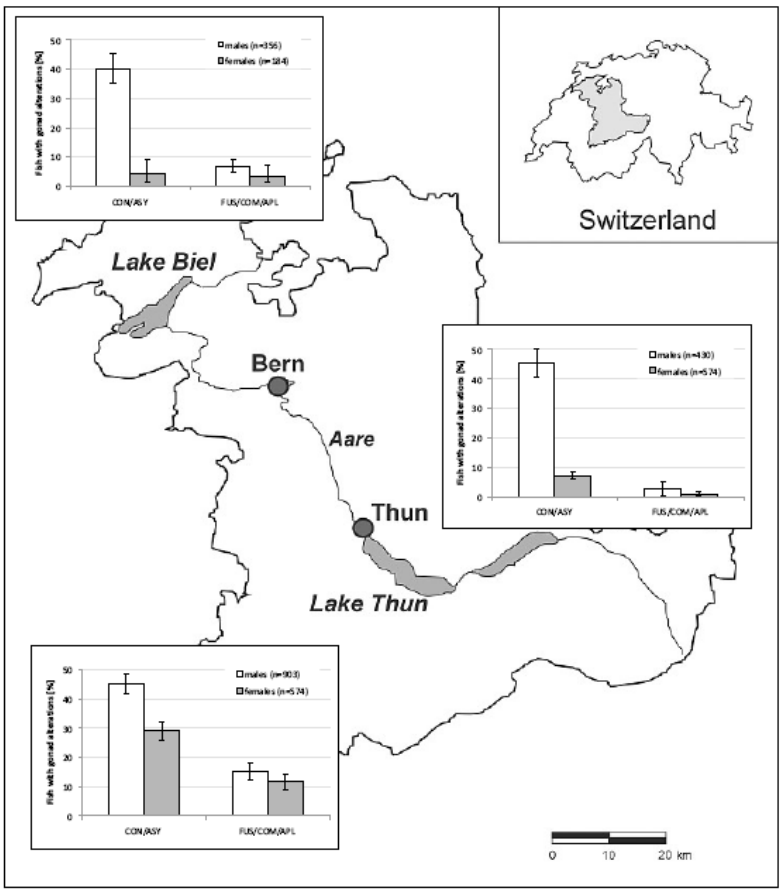

Fig. 2: Frequency of whitefish with gonad malformations in Lake Thun, Lake Brienz and Lake Biel. Data originate from a monitoring campaign in 2004 where all known spawning sites in the lakes were sampled.[8] Abbreviations: ASY = Asymmetries, CON = constrictions, FUS = Fusions (FUS), COM = Compartmentations, APL = Aplasia or atrophy.

for coregonids, environmental EDCs have been suspected as cause of gonad anomalies.[7]

The findings from field and laboratory studies on the induction of gonad morphological alterations by exposure of fish to EDCs, as well as the fact that morphological alterations of Lake Thun whitefish were restricted to the reproductive organs put the hypothesis forward that EDCs may be a causative factor. This leads to the question on potential sources of EDC contamination in the lake. An impact of effluents from STPs is unlikely, as there is only one substantial STP (population equivalent: 68'000) in the immediate vicinity of Lake Thun that releases its effluents directly into the lake. Atmospheric deposition is a major input pathway for polybrominated diphenyl ethers and related compounds which are suspected as endocrine disruptors, but their levels in Lake Thun are lower than in other lakes in which coregonid populations show no gonad alterations.[23] One important group of contaminants could be explosives from ammunition deposits. From the 1920s until the 1960s, the Swiss Army dumped approximately 4'600 tons of ammunition into Lake Thun. Certain explosive constituents including trinitrotoluenes were reported to have weak endocrine activities.[24] A further source of chemical contamination is the wastewater from the Lötschberg tunnel works which reaches Lake Thun *via* the River Kander, a main tributary of the lake. Chemicals used for the tunnel works include a wide range of substances, with various explosives and naphthalene sulfonates being major components (Cantonal Office for Water and Soil Protection, unpublished). Although the wastewater is pre-treated before release into the Kander, and diluted during the 25 km passage until the lake, it still can be a source of low-level contamination, as indicated from model calculations.

Experimental Approaches to Test the EDC Hypothesis for Lake Thun Whitefish

Based on the aforementioned considerations, the hypothesis was tested that the gonad malformations of Lake Thun whitefish are related to exposure to EDCs in the lake environment, be it in the water, in the food (lake plankton; coregonids rely on gill raker filter feeding) or in the sediment. Since to date the vast majority of known EDCs are those that interfere with the parts of the endocrine system associated with the sex steroid system, we focused on compounds acting as agonists or antagonists of the estrogen and androgen receptors. Additionally, we investigated the effects of key toxicants from potential contamination sources, *i.e.* ammunition dumps and Lötschberg tunnel wastewater.

Experimentally, we used the following approaches to test the EDC hypothesis:

Bio-analytical Studies on the Presence of Endocrine Activities in Water, Sediment, Plankton, and Whitefish of Lake Thun

Due to the fact that the identity of the compounds causing the malformations is unknown, the combination of bioanalytical screening together with effect-oriented analysis appears to be the most promising approach to search for the presence of EDCs in Lake Thun. Using this strategy, we performed a comprehensive monitoring of the habitat (Lake Thun water and sediment), the food chain (plankton) and fish (muscle and bile of whitefish with normal or malformed gonads). Reference samples were taken from Lake Brienz which hosts a coregonid population showing significantly fewer abnormal gonad morphological variations than Lake Thun.[8] For monitoring of the water compartment, passive samplers of the POCIS type were used.[25] Sediment samples were collected from the surface layers of coregonid spawning sites in Lake Thun and Lake Brienz.

After extraction of the samples, they were tested in the recombinant yeast estrogen/androgen screen (YES/YAS[26,27]). Samples with endocrine activity were then chemically analyzed for the target steroids estrone, 17β-estradiol and 17α-ethinylestradiol and further fractionated according to physicochemical properties in order to reduce the complexity of the sample. The obtained fractions were tested again in the YES/YAS system and positive fractions were analyzed by means of mass spectrometry. In order to be able to detect biological activities beyond the YES/YAS system, we additionally implemented the E-Screen, based on estrogen-sensitive breast cancer cells,[28] the Mol-

Table 1. Hepatic levels of vitellogenin (VTG) mRNA levels (quantified by means of real time RT-PCR) and circulating levels of androgens (quantified by means of ELISA) in male whitefish from four different sites in Lake Thun. Males are categorized into males with normal or with abnormal gonad morphology. Gonads were classified as abnormal if one or more of the following deviation types were present: aplasia, compartmentation, fusion and intersexuality. The values are medians ± SD, number of analysed fish, minimum and maximum values [N; min-max].

		VTG [Copies Vtg-mRNA/1000 copies 18s-RNA]		Testosteron [ng/ml plasma]		11-Keto-Testosteron [ng/ml plasma]	
Morph	Site	Normal males	Abnormal males	Normal males	Abnormal males	Normal males	Abnormal males
Brienzlig	Merligen	1.31 ± 21.45	0.87 ± 28.45		30.81		36.37
		[24; 0.01 - 106.36]	[15; 0.04 - 99.21]		[1; 30.81 - 30.81]		[1; 36.37 - 36.37]
	Faulensee	2.89 ± 20.45	0.85 ± 9.24	26.54 ± 49.40	20.67 ± 12.46	20.37 ± 6.51	15.53 ± 10.68
		[27; 0.02 - 70.19]	[17; 0.01 - 27.95]	[6; 19.28 - 30.65]	[13; 0.11 - 48.28]	[6; 8.9 - 27.92]	[13; 0.49 - 33.44]
Albock	Schifflätti	0.33 ± 3.92	3.89 ± 4.28	43.36 ± 19.65		62.81 ± 26.70	
		[11; 0.05 - 10.07]	[7; 0.004 - 12.10]	[8; 16.42 - 69.31]		[8; 19.44 - 96.83]	
	Gwatt	3.99 ± 4.61	9.86 ± 20.65	29.86 ± 22.5	29.89 ± 16.42	33.00 ± 19.59	30.53 ± 29.01
		[6; 0.31 - 12.26]	[3; 7.01 - 44.14]	[15; 8.24 - 77.61]	[5; 11.79 - 50.97]	[15; 0.29 - 74.43]	[5; 0.68 - 75.65]

DarT assay based on molecular marker responses in zebrafish embryos,[29] and the sediment contact assay with zebrafish early life stages.[30]

Extracts of passive samplers from Lake Thun, Lake Brienz and River Kander showed neither estrogenic nor androgenic potencies. Extracts of the sediment samples taken in 2005 showed no estrogenic or androgenic activity. In 2006, again no androgenic activity was found but two out of five samples from the Beatenbucht, a former ammunition dump site, showed estrogenic activity (Liedtke and Suter, unpublished). According to chemical analyses, the two samples contained neither estrone, 17β-estradiol nor 17α-ethinylestradiol; thus, the nature of the receptor-activating substances remains unknown. The sediments were also screened for heavy metals because metals could interfere with the endocrine system, but, metal concentrations were generally low and site differences were not found. Concentrated extracts of plankton (mixed zoo- and phytoplankton) showed no androgenic potencies, but estrogenic activities were detected in three bioassays (YES, E-screen, MolDarT assay). However, estrogenic activities were not only present in plankton extracts of Lake Thun but also in plankton extracts of reference lakes with coregonid populations showing normal gonad morphology. The obviously more widespread presence of estrogenic activities in plankton extracts argues against a causative relationship between plankton estrogenicity and gonad malformations in Lake Thun. Preliminary results from bioassay-directed fractionation of the plankton extracts point to degradation products of natural substances to be responsible for the activity observed in the YES assay (Liedtke and Suter, unpublished).

Biomarker Studies to Indicate Exposure of Whitefish in Lake Thun to EDCs

Several biomarkers that are indicative of exposure of fish to EDCs were analyzed in coregonids of Lake Thun:

- *Vitellogenin:* The induction of vitellogenin (VTG) is a well-established biomarker of exposure of male fish to estrogen receptor ligands.[31]
- *Sex steroids* (testosterone and 11-keto testosterone): Disturbances in sex steroid metabolism and levels of circulating sex steroids have been repeatedly observed in fish exposed to EDCs.[32]
- *Prevalence of intersex fish*: A histological feature frequently observed in fish exposed to estrogenic compounds is the presence of intersex gonads, or more specifically, ovotestis, *i.e.* gonads with predominantly testicular morphology but containing also ovarian morphology.[21,22]

For biomarker measurements, a total of 878 whitefish were collected in September and December 2005 and 2006 on four spawning sites, two of them ('Merligen' which is in close proximity to an ammunition dump site, and 'Faulensee') used by the summer spawning ecotypes 'Brienzlig' (the form with the highest prevalence of malformations, see above), and two other sites ('Schifflätti', 'Gwatt') used by the winter-spawning ecotypes 'Albock'. Despite distinct differences in the frequency of gonad alterations between Brienzlig and Albock, the two ecotypes showed no significant differences in hepatic VTG mRNA levels (Table 1). Also plasma levels of testosterone and 11-keto-testosterone did not differ significantly between male Brienzlig

Table 2. Frequencies of macroscopically abnormal gonads and intersex in male (M) and female (F) whitefish from four different sites in Lake Thun. Data indicate number of analyzed fish (N), frequency (f) of gonad malformations and its 95% confidence intervals (CI_{95}). Gonads were classified as abnormal if one or more of the following deviation types were present: aplasia, compartmentation, fusion and intersexuality.

			Macroscopy			Histology		
			Abnormal fish			Mosaic Intersex		
Morph	Site	Sex	N	*f*	CI_{95}	N	*f*	CI_{95}
Brienzlig	Merligen	M	100	0.37	0.28-0.47	39	0.15	0.06-0.31
		F	163	0.30	0.23-0.38	12	0	0.00-0.25
	Faulensee	M	249	0.37	0.31-0.43	44	0	0.00-0.08
		F	206	0.12	0.07-0.17	13	0	0.00-0.25
Albock	Schifflätti	M	63	0.19	0.10-0.31	18	0.02	0.00-0.27
		F	22	0.05	0.00-0.23	5	0	0.00-0.52
	Gwatt	M	40	0.15	0.06-0.30	9	0	0.00-0.34
		F	35	0.03	0.00-0.15	4	0	0.00-0.60

and male Albock (Table 1). Moreover, there were no significant differences in VTG mRNA or sex steroid levels between fish with malformed testes and fish with normal testes.

Intersex gonads were found at all sites with very low frequency in fish except at Merligen, where 15% of male whitefish displayed ovotestis (Table 2). The intersex gonads were of a mild form, with one or few oocytes scattered in normal testicular tissue, and they were neither correlated with elevated vitellogenin expression nor with altered plasma androgen concentrations.

Both the results of the bioanalytical and the biomarker studies do not point to relevant chemical or EDC exposure of fishes in the Lake Thun environment. This finding agrees well with the results of chemical-analytical studies showing that levels of chemical contamination in Lake Thun tends to be lower than in other lakes.[23,33]

Long-term Rearing of Coregonids under Exposure to Either Lake Thun Water or Plankton

The aim of the rearing experiments was to evaluate whether exposure of developing whitefish to Lake Thun water or plankton results in induction of gonad abnormalities, thereby indicating the presence of a causative factor in the Lake Thun ecosystem. The coregonids were reared from fertilization until early maturity at 2–3 years of age under exposure to either water or plankton from Lake Thun. For the experiments, both offspring from Lake Thun and Lake Biel were used in order to differentiate environmental and genetic factors. As negative controls, coregonids were reared in either spring water or in water of Lake Lucerne, and they were fed with dry feeds instead of lake plankton. A controlled breeding scheme was used with a view to obtain a multitude of known parental combinations. This allowed us to generate offspring from pairs of parent fish with normal or abnormal gonad morphology, and from mixed pairs.

Two sets of experiments were initiated, one in 2004 and, after part of the 2004 experiments had been lost due to a flooding event, a second set was started in 2005. While the latter experiments are still ongoing, the remaining groups of the first set were sampled in October 2007. A striking observation from this experiment is that the feed significantly influenced the development of gonad alterations: Among the males fed with Lake Thun plankton, 28% showed malformed testes, while among the females, 12% had malformed ovaries. In contrast, whitefish reared on dry feed displayed significantly lower percentages of malformations (males: 2–8%; females: 1–2%), independent of fish origin and water quality (spring water, Lake Lucerne water). It needs now to be clarified whether the results of the second rearing experiment (started in 2005) will confirm these findings.

Long-term Rearing of Coregonids under Exposure to Prototypic EDCs and Lake Thun Contaminants

Two types of contaminants were tested in these experiments. First, we investigated whether chemicals bound to the sediments may have organizational effects on gonad development of whitefish. The fertilized eggs of whitefish develop on the sediments until they reach the swim-up stage. During this period of life, the fish therefore could be exposed to bioavailable sediment-borne toxicants. Candidate contaminants in sediments of Lake Thun are chemicals originating from the dumped ammunition, for instance, trinitrotoluenes, as well as lipophilic chemicals originating from Loetschberg tunnel wastewaters that are transported *via* River Kander to Lake Thun and may bind to the sediments. In this context, naphthalene sulfonates (NSF) are of concern, as these compounds have been used in large volumes as additives to concrete constructions in the tunnel. Environmentally persistent NSF monomers leach out during concrete hardening[34] and, according to environmental fate modelling, could reach Lake Thun in the low microgram/l range (Cantonal Office for Water and Soil Protection, unpublished).

A novel incubation system had to be developed to be able to expose whitefish eggs on sediments. This system was used to incubate whitefish eggs from fertilization until hatching on artificial control sediments, on natural Lake Thun sediments, or on Lake Thun sediments spiked with either 2,4,6,-trinitrotoluene (TNT), a major ammunition constituent, or a mixture of four environmentally persistent congeners of NSF. After hatching, the fish were transferred into non-contaminated tap water and they are now reared with dry feeds. The fishes will reach the sampling age (2.5 years) in October 2008.

In a second long-term rearing experiment, we investigated the impact of the natural estrogen, 17β-estradiol (E2) – as prototype estrogen receptor ligand – on gonad development of whitefish. The questions to be answered in this experiment were

i) whether long-term estrogen exposure is able to induce gonadal morphological alterations in whitefish, and
ii) whether these alterations are identical or similar to those found in whitefish from Lake Thun.

Whitefish were reared from start-feeding up to an age of 2.5 years with either an estrogen-free control diet or with estrogen-spiked diets. Measurement of hepatic vitellogenin (VTG) mRNA was used to test the efficiency of the dietary E2 treatment and the results showed a dose-dependent induction. The estrogen treatment also led to a dose-dependent increase in the prevalence of intersex gonads (Kipfer *et al.*, in prep.). Importantly, however, while intersex is the gonad malformation showing the lowest frequency in whitefish from Lake Thun,[8] those malformations that are more frequent in wild fishes, *e.g.* fusions or aplasia, were not induced by the estrogen treatment. This finding argues against a causative role of estrogen receptor ligands in the induction of the gonad alterations of Lake Thun coregonids.

Conclusion

The objectives of this project were to evaluate i) whether the gonad alterations of whitefish in Lake Thun represent abnormal morphological variations specific to this lake, and, if so, ii) whether the malformations are related to chemical exposure, in particular to exposure to EDCs. Although the investigations are not fully completed yet, the results obtained so far provide strong evidence that certain alterations of the gonad morphology are indeed abnormal variations, and that the high frequency of malformations is a feature unique to coregonids of Lake Thun. The comparison of gonad morphologies of whitefish from the Lakes Thun, Brienz and Biel revealed that coregonids in all three lakes express some level of gonad morphological variation, but whitefish from Lake Thun, in particular the ecotype 'Brienzlig', show significantly higher prevalence of aplasias, compartmentations, fusions, and intersex gonads. A causative role of estrogen- or androgen-active EDCs in the development of the gonad malformations is not supported by the currently available data. The bioanalytical investigations found estrogenic activities in concentrated plankton extracts, but this was not a specific finding for Lake Thun and was observed in plankton extracts of other lakes as well. Biomarkers such as vitellogenin or gonad histopathology neither indicated estrogenic exposure of Lake Thun coregonids nor did they show differences between fish with normal and with malformed gonads. Exposure experiments with the positive control substance, 17β-estradiol, failed to induce the Lake Thun-typical gonad malformations. Initial results from feeding experiments with plankton of Lake Thun point to a role of the plankton in the formation of gonad malformations, however, this finding on the one hand needs to be confirmed in the ongoing experiments, and on the other hand does not necessarily implicate a role of EDCs. Overall, the current state of knowledge does not support an EDC or chemical etiology of the gonad malformations, but this preliminary conclusion needs to be further substantiated.

Acknowledgements

The financial support of NRP50 'Endocrine Disruptors: Relevance to Humans, Animals and Ecosystems' is gratefully acknowledged.

Received: March 22, 2008

[1] P. Steinmann, *Schweiz. Z. Hydrol.* **1951**, *12/13*.
[2] D. Bernet, T. Wahli, C. Küng, H. Segner, *Dis. Aquat. Org.* **2004**, *61*, 137.
[3] J. P. Sumpter, A. C. Johnson, *Environ. Sci. Technol.* **2005**, *39*, 4321.
[4] T. R. Porter, S. Corey, *J. Fish. Res. Board Can.* **1974**, *31*, 1944.
[5] K. Demska-Zakes, A., Mamcarz, in 'Conservation of endangered freshwater fish in Europe', Ed. A. Kirchhofer, D. Hefti, Birkhäuser, Basel, **1996**, p. 225.
[6] M. T. Kinnison, M. J. Unwin, F. Jara, *N. Z. J. Mar. Fresh. Res.* **2000**, *34*, 125.
[7] I. Mikaelian, D. Martineau, Y. De Lafontaine, J. C. Harshbarger, L. L. J. Lee, *Environ. Toxicol. Chem.* **2002**, *21*, 532.
[8] D. Bittner, D. Bernet, T. Wahli, H. Segner, C. Küng, C.R. Largiader, submitted.
[9] J. R. Hunter, B. J. Macewicz, *Fish Bull. Calif. Dep. Fish. Game* **1995**, *83*, 119.
[10] L. Norrgren, B. E. Bengtsson, H. Börjeson, Swedish Environmental Protection Agency, Report 4346, **1994**, Solna, p. 7
[11] T. Wicklund, L. Lounasheimo, J. Lom, G. Bylund, *Dis. Aquat. Org.* **1996**, *26*, 163.
[12] J. D. Fitzsimons, C. W. Cairns, *J. Gr. Lakes Res.* **2000**, *26*, 74.
[13] V. S. Blazer, *Fish Physiol. Biochem.* **2002**, *26*, 85.
[14] T. Wicklund, G. Bylund, *Bull. Europ. Assoc. Fish Path.* **1994**, *14*, 159.
[15] F. Förlin, L. Norrgren, *Ambio* **1998**, *27*, 411.
[16] R. M. Rolland, *Fish and Fisheries* **2000**, *1*, 41.
[17] L. T. L. M. van der Ven, P. W. Wester, J. G. Vos, *Environ. Toxicol. Chem.* **2003**, *22*, 908.
[18] C. Schäfers, M. Teigeler, A. Wenzel, G. Maack, M. Fenske, H. Segner, *J. Toxicol. Environ. Health A* **2007**, *70*, 768.
[19] Y. Allen, A. P. Scott, P. Matthiessen, S. Haworth, J. E. Thain, S. Feist, *Environ. Toxicol. Chem.* **1999**, *18*, 1791.
[20] A. D. Vethaak, J. Lahr, S. M. Schrap, A. C. Belfroid, G. B. J. Rijs, A. Gerritsen, J. de Boer, A. S. Bulder, G. M. C. Grinwijs, R. V. Kuiper, J. Legler, T. A. J. Murk, W. Peijnenburg, H. J. M. Verhaar, P. de Voogt, *Chemosphere* **2005**, *59*, 511.
[21] S. Jobling, M. Nolan, C. R. Tyler, G. Brighty, J. P.Sumpter, *Environ. Sci. Technol.* **1998**, *32*, 2498.
[22] S. Jobling, C. R. Tyler, *Pure Appl. Chem.* **2003**, *75*, 2219.
[23] M. Zennegg, M. Kohler, A. C. Gerecke, P. Schmid, *Chemosphere* **2003**, *51*, 545,
[24] European Commission, 'Towards the establishment of a priority list of substances for further evaluation of their role in endocrine disruption', **2000**, DG ENV, Delft.
[25] D. A. Alvarez, J. D. Petty, J. N. Huckins, T. L. Jones-Lepp, D. T. Getting, J. P. Goddard, S. E. Manahan, *Environ. Toxicol. Chem.* **2004**, *23*, 1640.
[26] E. J. Routledge, J. P.Sumpter, *Environ. Toxicol. Chem.* **1996**, *15*, 241.
[27] P. Sohoni, J. P.Sumpter, *J. Endocrinol.* **1998**, *158*, 327.
[28] A. M. Soto, C. Sonnenschein, K. L.Chung, M. F. Fernandez, N. Olea, F. O. Serrano, *Environ. Health Persp.* **1995**, *103*, 113.
[29] J. Muncke, R. I. L. Eggen, *Environ. Toxicol. Chem.* **2006**, *25*, 2734.
[30] H. Hollert, S. Keiter, N. König, M. Rudolf, M. Ulrich, T. Braunbeck, *J. Soils & Sediments* **2003**, *3*, 197.
[31] J. P. Sumpter, S. Jobling, *Environ. Health Persp.* **1995**, *103*, *suppl.* 7, 173.
[32] M. E. McMaster, G. L. van der Kraak, C. B.Portt, K. R. Munkittrick, P. K. Sibley, R. Smith, D. G. Dixon, *Aquat. Toxicol.* **1991**, *21*, 199.
[33] J. D. Berset, U. Ochsenbein, M. Zeh, *Chimia* **2007**, *61*, 532.
[34] S. Riediker, M. J. F. Suter, W. Giger, *Wat. Res.* **2000**, *34*, 2069.

SOP

VTG-MESSUNG MITTELS REAL-TIME RT-PCR

RNA-Extraktion & Messung

Homogenisierung

1. Gewebe homogenisieren (TissueLyser) in 1 ml TRIzol
2. Inkubation der Proben für 5’ bei RT

Phasentrennung

3. Zentrifugieren 12'000 rcf bei 4°C für 10’
4. Überstand in neues Tube geben, Pellet wegwerfen
5. Chloroform 0.2 ml/ml TRIzol beigeben
6. Schütteln für 15 s auf Vortex (Tubes gut schliessen)
7. Tubes ruhen lassen für 2’ bei RT
8. Zentrifugieren 10'000 rcf bei 4°C für 15’

RNA Fällung

9. Wässrige Phase abpipettieren (vorsichtig!!) und in Isopropanol 0.5 ml/ml TRIzol geben
10. vorsichtig durch Invertieren mischen
11. Entweder 10’ bei RT stehen lassen und weiterverarbeiten oder bei –80°C lagern

RNA waschen

12. Zentrifugieren 10'000 rcf bei 4°C für 10’
13. Überstand ableeren, Pellet mit 75% Ethanol (1 ml/ml TRIzol) kurz waschen (flippen und invertieren)
14. Zentrifugieren 10'000 rcf bei 4°C für 10’
15. Überstand ableeren, Pellet in Tube kurz trocknen (max. 5’ – 10’)
16. Zugabe von RNA Storage Solution 100 µl und Resuspendieren (flippen)
17. Inkubation bei 55°C für 5’ um Material zu resuspendieren
18. Downspin bei 4°C für 5’
19. 50 µl in neues Eppendorf geben, Pellet wegwerfen
20. DNA enzymatisch verdauen (siehe DNase Reaktion)

DNase Reaktion

1. 5 µl 10xBuffer zum Template (50 µl) geben
2. 1 µl DNase I dazugeben, sanft mischen
3. Inkubation 23’ bei 37°C
4. 5 µl DNase Inactivation Reagent dazugeben, sanft mischen
5. 2’ bei RT stehen lassen, weiter sanft mischen zwischendurch
6. Zentrifugieren 10'000 rcf für 90 s
7. Überstand abpipettieren (mind. 50 µl)

RNA-Menge messen (im Nano Drop)

1. Kalibrieren mit 1.6 µl Storage Solution
2. Templates messen
3. Ausrechnen: 1 µg RNA / 8 µl Template-Lösung

Reverse Transkription

1. Master-Mix mischen: 10 µl Buffer
   2 µl RNAse-Inhibitor
   2.5 µl 10mM dNTP
   2 µl M-MLV (Enzym)
   1 µl random hexamers (unspezifische Primer)
   auffüllen mit Aqua bi-dist. auf 42 µl
2. 8 µl Template zu 42 µl Master-Mix pippettieren (Endmenge = 50 µl)
3. 10’ bei 25°C, 60’ bei 42°C, 5’ bei 95°C inkubieren (PCR-Programm: „Richi“/RT-PCR)
4. => cDNA, bei –20° lagern

Real-time PCR

1. 1,5ml Tubes für 18s-Verdünnung beschriften
2. samples auftauen, flippen, short spin
3. Verdünnung samples für 18s: 999 µl DEPC H2O+ 1 µl sample; invertieren, short spin
4. Primer fwd, Primer rev, Probe VTG/18s auftauen: VTG-Primers, -Probes werden unverdünnt geliefert; Verdünnung siehe Lieferscheine
5. Primers, Probes vortexlen, short spin
6. 2x 2 ml Tubes für MasterMix beschriften
7. Universal PCR- MasterMix immer auf Eis
8. MasterMix: 6 µl dH2O

   12.5 µl Universal PCR- MasterMix

   1.25 µl Primer fwd

   1.25 µl Primer rew

   2 µl Probe
9. MasterMix fürs 18s: 9.75 µl dH2O

   12.5 µl Universal PCR- MasterMix

   0.25 µl Primer fwd

   0.25 µl Primer rew

   0.25 µl Probe
10. MasterMix vortexlen, short spin
11. samples flippen, short spin
12. pippettieren in wells: 23 µl MasterMix sample + 2 µl sample (gleiche Menge fürs 18 s reference gene)
13. caps gut schliessen, Platte vorsichtig flippen, short spin
14. Amplifikation in 7300 real-time PCR System: 50°C für 2 min, 95°C für 10 min, 95°C für 15 min mit 45 Wiederholungen, Endphase 60°C für 1 min